

**7.3 BIOCHEMISTRY
HISTOLOGY
MISCELLANEOUS**

7.3.1 TUBULOINTERSTITIAL DAMAGE AS THE MAJOR PATHOLOGICAL LESION IN ENDEMIC CHRONIC KIDNEY DISEASE AMONG FARMERS IN NORTH CENTRAL PROVINCE OF SRI LANKA

Tubulointerstitial damage as the major pathological lesion in endemic chronic kidney disease among farmers in North Central Province of Sri Lanka

Shanika Nanayakkara · Toshiyuki Komiya · Neelakanthi Ratnatunga · S. T. M. L. D. Senevirathna · Kouji H. Harada · Toshiaki Hitomi · Glenda Gobe · Eri Muso · Tilak Abeysekera · Akio Koizumi

Received: 31 August 2011 / Accepted: 16 September 2011
© The Japanese Society for Hygiene 2011

Abstract Chronic kidney disease of uncertain etiology (CKDu) in North Central Province of Sri Lanka has become a key public health concern in the agricultural sector due to the dramatic rise in its prevalence and mortality among young farmers. Although cadmium has been suspected as a causative pathogen, there have been controversies. To date, the pathological characteristics of the

disease have not been reported. Histopathological observations of 64 renal biopsies obtained at Anuradhapura General Hospital from October 2008 to July 2009 were scored according to Banff 97 Working Classification of Renal Allograft pathology. The correlations between the histological observations and clinical parameters were statistically analyzed. Interstitial fibrosis and tubular atrophy with or without nonspecific interstitial mononuclear cell infiltration was the dominant histopathological observation. Glomerular sclerosis, glomerular collapse, and features of vascular pathology such as fibrous intimal thickening and arteriolar hyalinosis were also common. Although hypertension was identified as one of the common clinical features among the cases, it did not influence the histopathological lesions in all the cases. This study concludes that tubulointerstitial damage is the major pathological lesion in CKDu. Exposure(s) to an environmental pathogen(s) should be systematically investigated to elucidate such tubulointerstitial damage in CKDu.

For the Chronic Kidney Disease of Uncertain Etiology Consortium.

S. Nanayakkara and T. Komiya contributed equally to this study.

A full list of Consortium members is provided in the Appendix.

Electronic supplementary material The online version of this article (doi:10.1007/s12199-011-0243-9) contains supplementary material, which is available to authorized users.

S. Nanayakkara · S. T. M. L. D. Senevirathna · K. H. Harada · T. Hitomi · A. Koizumi (✉)
Department of Health and Environmental Sciences,
Kyoto University Graduate School of Medicine,
Yoshida-Konoe, Sakyo-ku, 606-8501 Kyoto, Japan
e-mail: koizumi.akio.5v@kyoto-u.ac.jp

T. Komiya · E. Muso
Department of Nephrology and Dialysis, Tazuke Kofukai
Medical Research Institute Kitano Hospital, Osaka, Japan

N. Ratnatunga
Department of Pathology, Faculty of Medicine,
University of Peradeniya, Peradeniya, Sri Lanka

G. Gobe
Department of Molecular and Cellular Pathology,
School of Medicine, Princess Alexandra Hospital,
University of Queensland, Brisbane 4102, Australia

T. Abeysekera
Nephrology Unit, General Hospital (Teaching),
Kandy, Sri Lanka

Keywords Chronic kidney disease · Farmers · Cadmium · Histopathology · Sri Lanka

Introduction

Chronic kidney disease (CKD) is an emerging public health problem globally because of its increasing prevalence and its associated adverse clinical outcomes, poor quality of life, and high healthcare costs [1, 2]. During the past two decades, an endemic condition of CKD has become prevalent among the low-socioeconomic farming community in the North Central Province (NCP) of Sri Lanka, which is the main agricultural region in the country. Those communities are mainly composed of immigrants

from southern parts of Sri Lanka where CKD has not been prevalent. They settled in this region during the development of new irrigation projects in NCP. CKD became prevalent among the immigrant communities, and currently it has become the leading cause of death in this region [3, 4]. Male paddy farmer preponderance, insidious onset, and progression with late presentation when renal replacement therapy is necessary are characteristics of CKD in this particular region. Because of the analogy of the endemic nature of CKD in Sri Lanka to *itai-itai* disease, a cadmium hypothesis has emerged recently [5–7]. However, intensive ecological investigations did not support the cadmium hypothesis [3]. It is known as “chronic kidney disease of uncertain etiology” (CKDu), since investigations so far have not been able to identify the attributable risk factor(s) [3].

There is no report on the pathological characteristics of CKDu, even though renal biopsy is considered the gold standard to establish diagnosis, especially when the cause is not obvious from other investigations [8, 9]. Histopathological characteristics can provide important clues on candidate pathogens [9]. In the absence of previous published evidence of the underlying pathology, this study aims to search for possible pathogen(s) based on the histopathological evidence.

Subjects and methods

Ethical statement

Ethical approval for the study was obtained from Kyoto University, Japan and the University of Peradeniya, Sri Lanka. All clinical records and biological samples were obtained after receiving informed consent from patients.

Study design

Subjects

Sixty-four CKDu patients who underwent renal biopsy at Anuradhapura General Hospital in Sri Lanka during the period from October 2008 to July 2009 were recruited for this study. In the Sri Lankan medical system, it is the responsibility of patients to keep the clinical records provided by the local hospital. Personal and clinical information were collected by face-to-face interviews and through clinical records which were available from the patients. Such information included age, sex, occupation, evidence of having hypertension (history or current treatment with antihypertensive medicine), latest serum creatinine level, and the latest ultrasonographic findings on bipolar length (BPL) of the kidneys.

Differential diagnosis and diagnostic criteria

Patients with CKDu were diagnosed after excluding known etiologies. Diabetes mellitus was excluded by absence of history of diabetes mellitus, no current treatment for diabetes mellitus, and HbA1C <6.5%. Malignant hypertension was excluded by the absence of history of chronic and/or severe hypertension, with blood pressure <160/100 mmHg untreated or <140/90 mmHg on up to two antihypertensive agents. Systemic lupus erythematosus was excluded by the absence of anti-nuclear antibody (ANA) and antibody for double-strand DNA (dsDNA). Immunoglobulin (Ig) A nephropathy was excluded by immunostaining the biopsy sections for IgG, IgM, IgA, and C3. Urological diseases of known etiology were excluded by clinical symptoms and routine investigations.

Staging

Staging of patients was done using glomerular filtration rate (GFR) following the National Kidney Foundation Kidney Disease Outcome Quality Initiative guidelines (hereafter referred to as CKDu stages) [10]. The modified diet in renal disease (MDRD) formula [$GFR (ml/min/1.73m^2) = 186 \times \text{serum creatinine (mg/dL)}^{-1.154} \times (\text{age})^{-0.203} \times (0.742 \text{ if female}) \times (1.212 \text{ if African American})$] using serum creatinine levels was used to estimate GFR [11]. In most healthy people, GFR is 90 ml/min/1.73 m² or higher. However, people with GFR ≥ 90 ml/min/1.73 m² but with evidence of kidney damage were included in the patients with stage 1 CKDu. Patients with GFR in the ranges 60–89, 30–59, and 15–29 ml/min/1.73 m² were assigned to stages 2, 3, and 4, respectively. If GFR was <15 ml/min/1.73 m², patients were considered as stage 5 or end-stage patients [10].

Histopathology

The renal biopsy specimens were fixed in 10% formalin and embedded in paraffin. Sections of 3- μ m thickness were analyzed after hematoxylin–eosin (H&E), periodic acid–Schiff (PAS), periodic acid–Schiff silver methenamine (PASM), and Masson’s trichrome staining. Histological examinations were made independently without reference to the CKDu stage information by independent pathologists in Kitano Hospital, Japan and University of Queensland in Australia. These pathologists were blinded to all clinical and laboratory data. Histological changes in all 3 anatomic compartments in renal tissue (glomeruli, tubulointerstitium, and blood vessels) were assessed and scored or recorded as percentages or defined grades.

Glomerular lesions

The total number of glomeruli, globally sclerotic glomeruli, collapsed glomeruli, and glomeruli with segmental sclerosis were counted. The global glomerulosclerosis and glomerular collapse were recorded as percentages (global glomerulosclerosis score = sclerotic glomeruli/total glomeruli × 100%; collapsed glomeruli score = collapsed glomeruli/total nonsclerotic glomeruli × 100%). The number of specimens with glomerular enlargement was counted when at least one glomerulus showed a diameter over 200 μm. The specimens with glomeruli showing focal segmental glomerulosclerosis (FSGS) were counted separately. The specimens were checked for the presence of mesangial, endocapillary, and extracapillary cell infiltration.

Tubulointerstitial lesions

The severity of interstitial cell infiltration and the degree of interstitial fibrosis were assessed according to the Banff 97 Working Classification of Renal Allograft pathology [12]. Quantitative criteria for interstitial fibrosis ("ci")

- ci0 Interstitial fibrosis in up to 5% of cortical area
- ci1 Mild-interstitial fibrosis in 6–25% of cortical area
- ci2 Moderate-interstitial fibrosis in 26–50% of cortical area
- ci3 Severe-interstitial fibrosis in >50% of cortical area

Quantitative criteria for mononuclear cell interstitial inflammation ("i")

- i0 No or trivial interstitial inflammation (<10% of unscarred parenchyma)
- i1 10–25% of parenchyma inflamed
- i2 26–50% of parenchyma inflamed
- i3 More than 50% of parenchyma inflamed

All the specimens were assessed for presence of tubulitis. Presence of subcapsular cortical atrophy was checked and recorded separately.

Vascular lesions

Quantitative criteria for vascular fibrous intimal thickening and for arteriolar hyaline thickening in the Banff classification were used to assess the type and severity of small artery and arteriolar pathological lesions in specimens within which blood vessels could be observed ($N = 53$) [12].

Quantitative criteria for vascular fibrosis intimal thickening ("cv")

- cv0 No chronic vascular changes
- cv1 Vascular narrowing of up to 25% luminal area
- bv fibrointimal thickening of arteries ± breach of

internal elastic lamina or presence of foam cells or occasional mononuclear cells (in the most severely affected vessel)

- cv2 Increased severity of changes described above with 26–50% narrowing of vascular luminal area (in the most severely affected vessel)
- cv3 Severe vascular changes with >50% narrowing of vascular luminal area (in the most severely affected vessel)

Quantitative criteria for arteriolar hyaline thickening ("ah")

- ah0 No PAS-positive hyaline thickening
- ah1 Mild to moderate PAS-positive hyaline thickening in at least one arteriole
- ah2 Moderate to severe PAS-positive hyaline thickening in more than one arteriole
- ah3 Severe PAS-positive hyaline thickening in many arterioles

In addition, presence of vasculitis in different size arteries and observations compatible with thrombotic microangiopathy were also assessed.

Comparison between histological observations and clinical parameters

To evaluate the possibility of renal pathological lesions to predict CKDu severity and to determine the clinical and demographic factors which can influence the severity of the disease, we assessed the correlation between each lesion with age, presence of hypertension, serum creatinine, and GFR. Correlations among different histopathological observations and clinical parameters were further evaluated.

Statistical analysis

The results of global sclerosis score and collapsed glomeruli score are expressed as mean ± standard deviation (SD). The remainder of the scores are categorized and expressed as percentages. Pathological findings and clinical observations were further studied by two different statistical tests. The correlations between each pathological lesion and recorded noncategorical demographic and clinical parameters such as age, serum creatinine, GFR, and BPL of kidneys were analyzed using Spearman's rank correlation coefficients. The same analysis was performed to evaluate the correlation between observed histopathological features.

The readings of each parameter were stratified (analyzed one by one) according to hypertension (yes or no), focal subcortical atrophy (yes or no), and arteriolar hyalinosis (yes or no). Welch's *t*-test for unequal variance was used to

check the difference between two groups within the parameter. *P* values less than 0.05 were considered statistically significant, while values between 0.05 and 0.1 were considered as suggestive of significance.

All statistical procedures were performed using SAS version 9.1 (supplied by SAS Institute Inc., Cary, NC, USA).

Results and discussion

Of the 64 biopsies obtained from October 2008 to July 2009, only 57 biopsies were suitable for study due to inadequate sample size in 7 biopsies. The selected 57 renal biopsies were from patients of CKDu stage 1–4 (males = 42, female = 15). The male predominance was similar to in previous studies done in Europe and Australia [13, 14]. The mean age of the CKDu patients at time of biopsy was 45 ± 10.5 years. This emphasizes that this CKDu population is relatively younger. Renal biopsies from CKDu stage 5 were not available during this period because renal biopsies are not routinely obtained from end-stage patients due to small shrunken kidneys.

Histopathological observations

Histological observations of 57 renal biopsy specimens are summarized in Table 1 and Fig. 1.

Glomerular lesions (Fig. 1)

Global sclerosis was the most frequently observed pathological lesion, with average score of 37.1 ± 4.0%. The presence of collapsed glomeruli was relatively less common (17.6 ± 3.7%).

Frequent global sclerosis, ischemic-type obsolescence, and wrinkled and collapsed glomerular tufts were suggestive of ischemia of glomeruli, which is a common lesion in essential hypertension (Fig. 1) [15]. Glomerular enlargement was observed in 21 renal biopsy specimens (36.8%), being the second most common lesion in glomeruli. This can be due to compensatory hypertrophy of healthy nephrons following global sclerosis in other glomeruli and the associated atrophy of nephrons, which has been demonstrated in patients with essential hypertension [16].

It is noteworthy that the typical FSGS lesion of perihilar variant was observed in two specimens with nonnephrotic range of proteinuria (Fig. 1). This type of observation is highly suggestive of the existence of relatively long-term progressive loss of nephrons.

In contrast to the frequently observed sclerotic lesions, no specimen showed endocapillary, extracapillary, or mesangial cell proliferation as occurs in chronic glomerulonephritis and diabetic glomerulosclerosis [17]. No PAS-positive

Table 1 Summary of histopathological observations

Histopathological observation/score	Cases	Percentage positivity (%)
Glomerular pathology (N = 57)		
Focal segmental glomerulosclerosis	2	3.5
Glomerular enlargement	21	36.8
Global sclerosis score		37.1 ± 4.0 ^a
Collapsing glomeruli score		17.6 ± 3.7 ^a
Tubulointerstitial pathology (N = 57)		
Mononuclear cell interstitial inflammation score		
i0	23	40.4
i1	21	36.8
i2	12	21.0
i3	1	1.8
Interstitial fibrosis score		
ci0	4	7.0
ci1	18	31.6
ci2	20	35.1
ci3	15	26.3
Vascular pathology (N = 53)		
Fibrous intimal thickening score		
cv0	27	50.0
cv1	21	40.5
cv2	5	9.5
cv3	0	0
Arteriolar hyaline thickening score		
ah0	22	41.5
ah1	21	39.6
ah2	10	18.9
ah3	0	0
Other observations		
Focal subcapsular cortical atrophy	21	36.8

^a Mean ± SD

depositions compatible with immune complexes were noted. Supporting immunostaining for ANA and dsDNA confirmed the absence of mesangial and paramesangial deposition of immune complexes, excluding immune-complex-mediated pathology as occurs in conditions such as IgA nephropathy [15].

Tubulointerstitial lesions (Fig. 2)

Mononuclear cell interstitial inflammation score was i0 in 23 cases, i1 in 21 cases, i2 in 12 cases, and i3 in only 1 case (Table 1). It is noteworthy that, in almost all instances, inflammatory infiltrate predominantly contained mononuclear cells. The presence of eosinophils and plasma cells, which are representative of some kinds of allergic and hypersensitive interstitial nephritis, was a rare observation (*n* = 1) [18]. Tubulitis with invasion of tubular cells by

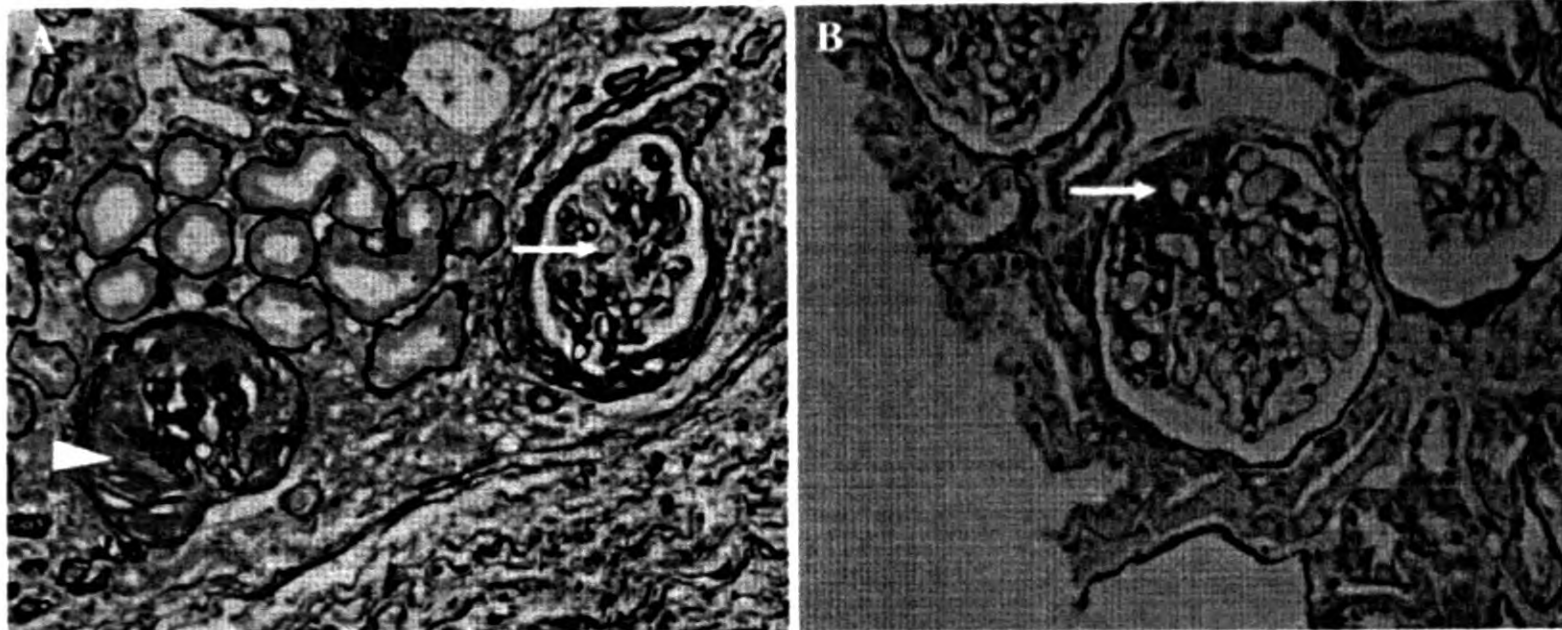


Fig. 1 Glomerular pathology. **a** Ischemic glomerular obsolescence. The glomerular capillary tufts are wrinkled and collapsed (*arrow*). Bowman's space is filled with collagen (*arrow head*) (PASM $\times 200$).

b Perihilar focal segmental glomerulosclerosis. The perihilar segment is obliterated by increased matrix and hyalinosis (*arrow*) (PAS $\times 200$)

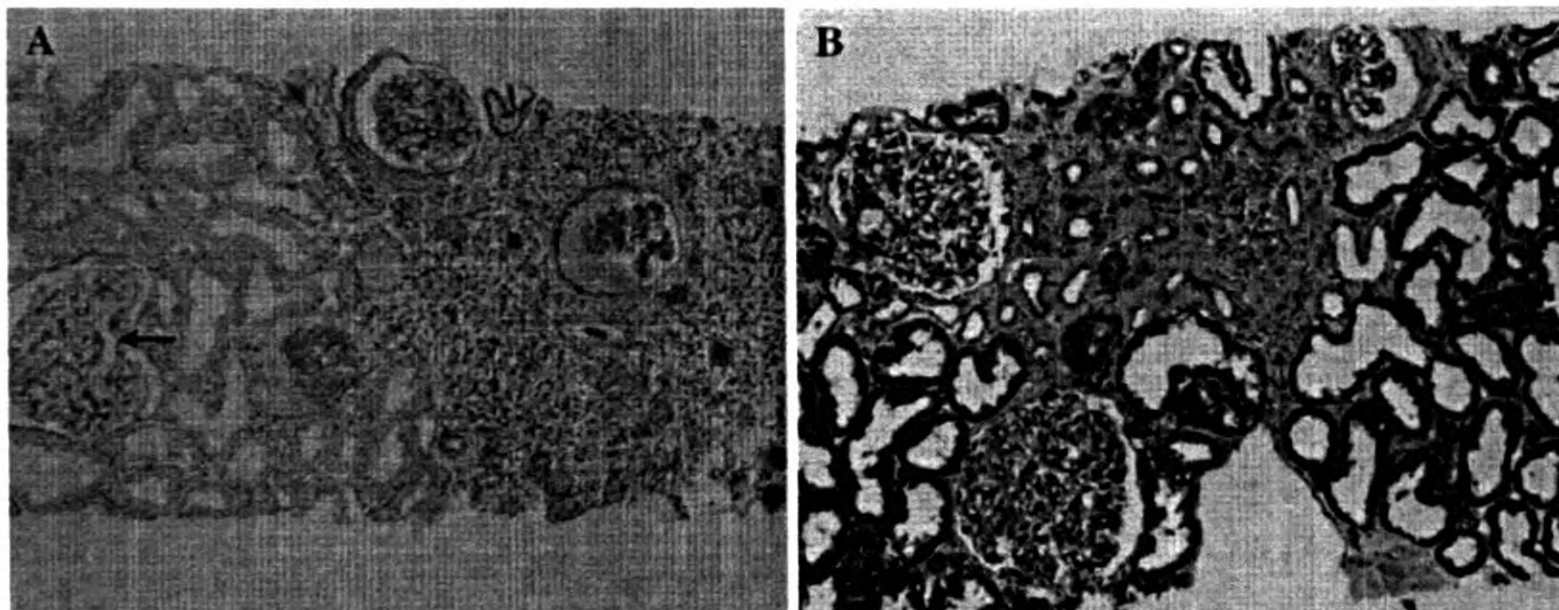


Fig. 2 Tubulointerstitial pathology. **a** Interstitial inflammation. Obsolescent glomeruli, tubular atrophy, and interstitial mononuclear cell infiltration are seen on the *right side*. A hypertrophic nephron is

seen on the *left side* (*arrow*) (PAS $\times 40$). **b** Interstitial fibrosis. Tubular atrophy and interstitial fibrosis can be seen (Masson's trichrome $\times 100$)

inflammatory cells was never observed. This reflects that the origin of this interstitial nephritis-like lesion is unlikely to be inflammation of tubular cells. In addition, tubular regeneration could not be observed in these specimens. In contrast to the relatively frequent cases without interstitial cell infiltration (23/57, 40.4%), only 4 cases (7%) were free of interstitial fibrosis (Table 1).

Vascular lesions (Fig. 3)

Arteriolar hyaline thickening score and fibrous intimal thickening score revealed the presence of mild to moderate vascular lesions in these patients (Table 1). Histological characteristics of vasculitis such as vessel-wall leukocyte infiltration or necrosis were not observed in any of the specimens. Frequently observed massive vascular sclerotic

lesions, even in relatively younger patients, were characteristic of these specimens. Frequently observed glomerular sclerosis and vascular lesions such as fibrous intimal thickening (Fig. 3a) and arteriolar hyalinosis have been reported as characteristics in hypertensive nephrosclerosis [19–21]. It should be noted that, although malignant hypertension was excluded, almost half of the patients ($n = 29$) had mild hypertension and were on antihypertensive medicine.

Some other important observations were the presence of subcapsular cortical atrophy (Fig. 3b) and vascular intimal cell swelling with subendothelial hyaline deposition, which are compatible with the subacute phase of thrombotic microangiopathy, in a limited number of specimens. The present study revealed that tubulointerstitial lesions sometimes accompanied by massive interstitial mononuclear

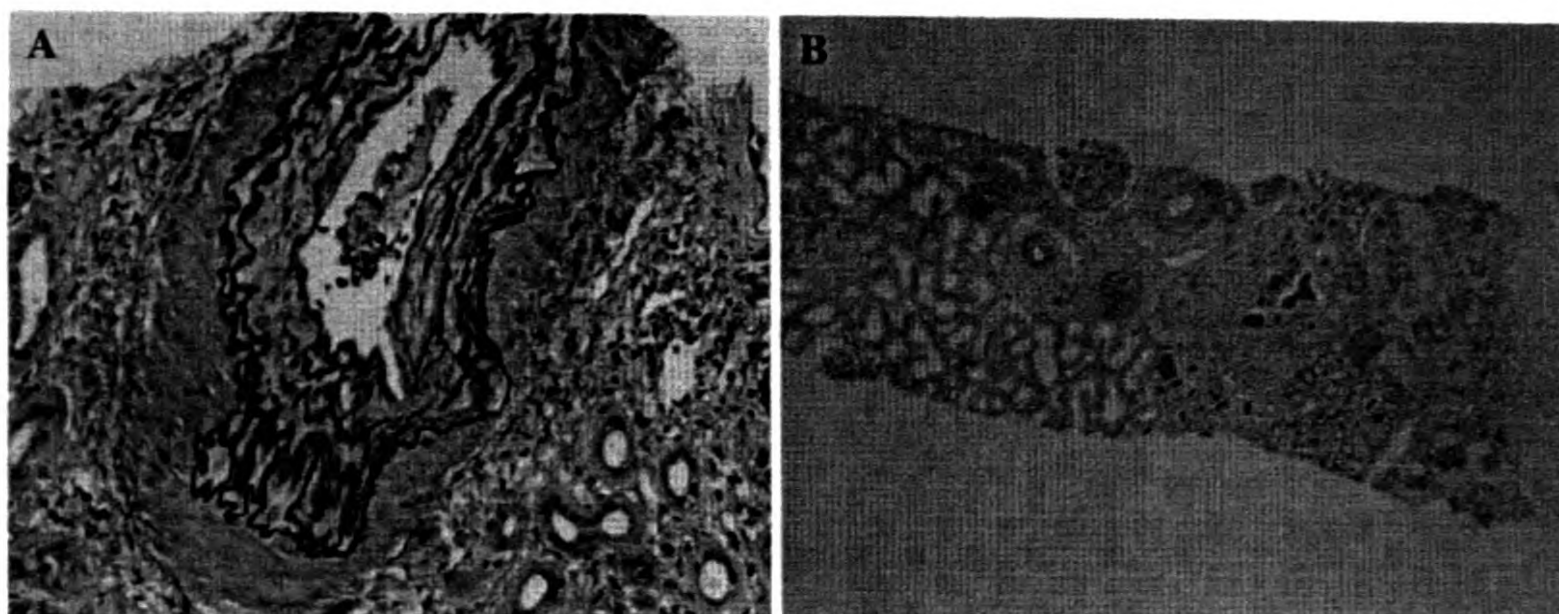


Fig. 3 Vascular pathology and subcapsular cortical atrophy. **a** Arteriosclerosis (intimal fibrosis). An interlobular artery showing fibrous thickening of the intima and elastosis is seen (Masson's trichrome

$\times 200$). **b** Subcapsular cortical atrophy. Subcapsular fibrotic area contains obsolete glomeruli, atrophic tubules, and chronic inflammation (PAS $\times 40$)

cell infiltration was the primary lesion of CKDu, while glomerular and vascular lesions were more likely subordinate ones. The current conclusion is in accordance with our previous findings in urine analysis in CKDu patients at stage 1–3, which demonstrated that the most subtle change in the urine was elevation of the tubular marker, alpha-1 microglobulin [22].

Clinicopathological correlation

Evaluation of the association of the histopathological observations with clinical parameters was limited to 56 cases (1 case was eliminated due to lack of data). Of these, 31 cases (55%) had hypertension at time of renal biopsy. Regarding the correlation with vascular pathology, 53 cases whose biopsy specimen contained blood vessels were evaluated. There was no association between gender and histopathological parameters. Welch's *t*-test revealed that hypertension had a significant association with presence of arteriolar hyalinosis, interstitial inflammation, and interstitial fibrosis in renal specimens (Table 2). Supplementary table 1 provides the difference in histopathological scores and the presence of each histopathological observation among cases with and without hypertension.

Correlations between combinations of clinical parameters and pathological observations were further evaluated using Spearman's rank correlation coefficient (ρ) (Table 3). Among the clinicopathological parameters compared, the greatest positive correlation was present between the age of the CKDu patients and the fibrous intimal thickening score. Serum creatinine concentration had a weak positive correlation ($P < 0.1$) with both interstitial fibrosis score and interstitial inflammation score. The greatest negative correlation was seen between GFR and the interstitial fibrosis score.

Table 2 Clinicopathological correlation (Welch's *t*-test)

Combination of variables	<i>P</i> value
Hypertension–arteriolar hyalinosis	0.02
Hypertension–interstitial fibrosis	0.06
Hypertension–interstitial inflammation	0.10
Arteriolar hyalinosis–serum creatinine	0.16
Arteriolar hyalinosis–age	0.49
Hypertension–fibrous intimal thickening	0.2
Hypertension–focal subcortical atrophy	0.54
Focal subcortical atrophy–serum creatinine	0.62
Hypertension–glomerular hypertrophy	0.77
Hypertension–sclerotic glomeruli	0.82
Hypertension–collapsed glomeruli	0.93

It is interesting that, even though we observed good correlation between tubulointerstitial lesions and clinical parameters such as hypertension and serum creatinine, none of the clinical parameters had good correlation with the glomerular pathology (Tables 2, 3). In contrast to the fibrous intimal thickening score, which had a relatively good correlation with age of the patients, the arteriolar hyaline score did not have a good correlation with age. However, it should be noted that hypertension had a significant correlation with arteriolar hyalinosis. Collectively, these observations suggest that the vascular pathology may be the result of long-standing hypertension.

Among the pathological parameters compared, the strongest positive correlation was observed between interstitial fibrosis and interstitial inflammation scores. Relatively strong positive correlation was observed between fibrous intimal thickening score and arteriolar hyaline score which categorize the vascular lesions in the renal tissue

Table 3 Clinicopathological correlation (Spearman's rank correlation coefficient)

Combination of variables	ρ^a	P value
Age–fibrous intimal thickening score	0.3708	0.02
Serum creatinine–interstitial fibrosis score	0.2953	0.04
Serum creatinine–interstitial inflammation score	0.2394	0.09
Serum creatinine–arteriolar hyaline thickening score	0.2020	0.17
Age–arteriolar hyaline thickening score	0.1830	0.19
Serum creatinine–fibrous intimal thickening score	0.1584	0.36
Age–interstitial fibrosis score	0.1312	0.33
Age–interstitial inflammation score	–0.0302	0.82
Glomerular filtration rate–fibrous thickening score	–0.1506	0.36
Glomerular filtration rate–arteriolar hyaline thickening score	–0.1719	0.23
Glomerular filtration rate–interstitial inflammation score	–0.2177	0.11
Glomerular filtration rate–interstitial fibrosis score	–0.2703	0.05

^a Spearman's rank correlation coefficient

Table 4 Correlation among pathological parameters (Spearman's rank correlation coefficient)

Combination of variables	ρ^a	P value
Interstitial inflammation score–interstitial fibrosis score	0.7869	<0.0001
Fibrous intimal thickening score–arteriolar hyalinosis score	0.4442	0.0036
Interstitial fibrosis score–arteriolar hyalinosis score	0.3156	0.0213
Interstitial fibrosis score–fibrous intimal thickening score	0.2651	0.0898
Interstitial inflammation score–arteriolar hyalinosis score	0.2041	0.1426
Interstitial inflammation score–fibrous intimal thickening score	0.2014	0.2010

^a Spearman's rank correlation coefficient

(Table 4). We did not observe a close correlation between interstitial fibrosis and vascular pathology.

Weighing all the observations, interstitial fibrosis often associated with interstitial inflammation appears to be the key factor determining the deterioration of renal function in CKDu patients.

We demonstrate herein that tubulointerstitial damage is the major pathological event in CKDu. A number of environmental and occupational nephrotoxins are known to cause similar type of renal injury [23]. A prototypical example of tubulointerstitial damage is *itai-itai* disease, in

which renal tubular damage and osteomalacia are characteristic features. It has been found in the cadmium-polluted Toyama Prefecture of the Jinzu River Basin in Japan [23, 24]. Because of the similarity observed in the endemic nature of the two diseases, in the recent past, some reports suggested cadmium-induced renal pathology in CKDu. It was suggested that agrochemicals containing cadmium are responsible for the toxic levels in the environment [6, 7].

Even though cadmium nephropathy is also characterized by interstitial fibrosis and tubular atrophy [25], in our previous studies we confirmed the absence of evidence supporting cadmium-induced renal disease in the endemic region [3]. We evaluated urinary alpha-1 microglobulin and cadmium levels in cases with mild stages of CKDu [22]. Although we found significant increase of alpha-1 microglobulin excretion in the urine from cases, we failed to detect elevation of urinary excretion of cadmium. Therefore, it is less likely that cadmium exposure plays an important role in the development of CKDu as reported by others [6].

Balkan endemic nephropathy (BEN) and Chinese herb nephropathy (CHN) are two well-known chronic tubulointerstitial renal disease syndromes [26, 27]. BEN and CHN have been associated with a natural toxin, aristolochic acid, as a key causative nephrotoxin [2, 28, 29]. However, in contrast to the Balkan region, which has a relatively high incidence of upper urinary tract tumors, urothelial tumors are a rare occurrence in the CKDu endemic region [30]. The interstitial inflammatory reaction, which was a frequent observation in CKDu (Fig. 2a), is not a significant feature of BEN [26, 29]. However, *Aristolochia* has been commonly used in the endemic community as a herb of traditional medicine. Thus, there remains a possibility of involvement of aristolochic acids in CKDu. Ochratoxin A is also a known environmental natural nephrotoxin resulting in tubular atrophy and interstitial fibrosis following chronic exposure [31]. Preliminary studies on urinary mycotoxins have shown relatively higher levels of ochratoxin A in CKDu patients and endemic controls, indicating a relatively higher exposure which needs further confirmatory investigations [32].

Still other possibilities such as glucose-6-phosphate dehydrogenase (G6PD) deficiency or G6PD carrier state, which are known to increase susceptibility to hemolysis-induced organ damage following exposure to certain classes of chemicals including some drugs, pesticides, and fungicides, may be associated with CKDu [33–35]. In the immigrant farming communities, discernible portions of population have G6PD deficiency or carrier state. Finally, we found in the environmental study that excessive exposure to fluoride occurred in the immigrant communities through drinking water [3]. It is well established that excess exposure to fluoride causes renal tubular damage [36].

Thus, there is a possibility that intensive exposure to fluoride may be a causative or modifying factor for developing CKDu.

Future investigations will be carried out to search for candidate environmental pathogens, giving emphasis to possibilities related to agricultural activities, natural nephrotoxins, high fluoride exposure through drinking water, and genetic susceptibility in the endemic area.

Acknowledgments The authors would like to thank Dr. Arjuna Dandeniya, Dr. Gayan Wijesundara, and Dr. Amila Kodikara, temporary lecturers at the Department of Pharmacology, Faculty of Medicine, University of Peradeniya, Sri Lanka for their tremendous support in this study. This study was supported by the Special Coordination Funds for Promoting Science and Technology from the Ministry of Education, Culture, Sports, Science, and Technology in Japan. The funding agency had no role in the study design, data collection and analysis, or in the decision to publish or in the preparation of the manuscript.

Appendix

The present members of the CKDu consortium and their affiliations are as follows: Rohana Chandrajith, Ayanthi Navarathna (Faculty of Science, University of Peradeniya), N. Ratnatunga, Dhammika Dissanayake, Nimmi Aturaliya, K. Jayasekara (Faculty of Medicine, University of Peradeniya), Tilak Abeysekera, A.W.M. Wazeel, Upul Karunaratne, K.U. Senaviratne, E.D.L. Gunaratne (General Hospital Kandy (Teaching)), C.B. Dissanayake, J.P. Padmasiri (Institute of Fundamental Studies), C.M. Madduma Bandara (University of Peradeniya), Akio Koizumi, Kouji H. Harada, Toshiaki Hitomi, Shanika Nanayakkara, Lalantha Senevirathna (Kyoto University Graduate School of Medicine), Eri Muso, Toshiyuki Komiya, Yoshiaki Yuba (Kitano Hospital), Takao Watanabe (Tohoku Bunkyo University), Koichi Haraguchi (Daiichi University of Pharmacy), Wendy Hoy, Glenda Gobe, Susan Mott (University of Queensland).

References

1. Manns B, Hemmelgarn B, Tonelli M, Au F, Chiasson TC, Dong J, Klarenbach S. Population based screening for chronic kidney disease: cost effectiveness study. *BMJ*. 2010;341:c5869.
2. Soderland P, Lovckar S, Weiner DE, Brooks DR, Kaufman JS. Chronic kidney disease associated with environmental toxins and exposures. *Adv Chronic Kidney Dis*. 2010;17:254–64.
3. Chandrajith R, Nanayakkara S, Itai K, Aturaliya TN, Dissanayake CB, Abeysekera T, Harada K, Watanabe T, Koizumi A. Chronic kidney diseases of uncertain etiology (CKDu) in Sri Lanka: geographic distribution and environmental implications. *Environ Geochem Health*. 2011;33:267–78.
4. Wanigasuriya KP, Peiris-John RJ, Wickremasinghe R, Hittarage A. Chronic renal failure in North Central Province of Sri Lanka:

an environmentally induced disease. *Trans R Soc Trop Med Hyg*. 2007;101:1013–7.

5. Kawano S, Nakagawa H, Okumura Y, Tsujikawa K. A mortality study of patients with Itai-itai disease. *Environ Res*. 1986;40:98–102.
6. Bandara JM, Senevirathna DM, Dasanayake DM, Herath V, Abeysekera T, Rajapaksha KH. Chronic renal failure among farm families in cascade irrigation systems in Sri Lanka associated with elevated dietary cadmium levels in rice and freshwater fish (Tilapia). *Environ Geochem Health*. 2008;30:465–78.
7. Bandara JM, Wijewardena HV, Liyanage J, Upul MA. Chronic renal failure in Sri Lanka caused by elevated dietary cadmium: Trojan horse of the green revolution. *Toxicol Lett*. 2010;198:33–9.
8. Khajehdehi P, Junaid SM, Salinas-Madrigal L, Schmitz PG, Bastani B. Percutaneous renal biopsy in the 1990s: safety, value, and implications for early hospital discharge. *Am J Kidney Dis*. 1999;34:92–7.
9. Howie A. Renal Biopsy. *Medicine Renal J*. 2003;31:29–31.
10. Foundation NK KDOQI Clinical Practice Guidelines for Chronic Kidney Disease. Evaluation, classification, and stratification. http://www.kidney.org/professionals/KDOQI/guidelines_ckd/toc.htm. Accessed 26 Dec 2010.
11. Kooman JP. Estimation of renal function in patients with chronic kidney disease. *J Magn Reson Imaging*. 2009;30:1341–6.
12. Racusen LC, Solez K, Colvin RB, Bonsib SM, Castro MC, Cavallo T, Croker BP, Demetris AJ, Drachenberg CB, Fogo AB, Furness P, Gaber LW, Gibson IW, Glotz D, Goldberg JC, Grande J, Halloran PF, Hansen HE, Hartley B, Hayry PJ, Hill CM, Hoffman EO, Hunsicker LG, Lindblad AS, Yamaguchi Y, et al. The Banff 97 working classification of renal allograft pathology. *Kidney Int*. 1999;55:713–23.
13. Rivera F, Lopez-Gomez JM, Perez-Garcia R. Clinicopathologic correlations of renal pathology in Spain. *Kidney Int*. 2004;66:898–904.
14. Briganti EM, Dowling J, Finlay M, Hill PA, Jones CL, Kincaid-Smith PS, Sinclair R, McNeil JJ, Atkins RC. The incidence of biopsy-proven glomerulonephritis in Australia. *Nephrol Dial Transplant*. 2001;16:1364–7.
15. Hughson MD, Johnson K, Young RJ, Hoy WE, Bertram JF. Glomerular size and glomerulosclerosis: relationships to disease categories, glomerular solidification, and ischemic obsolescence. *Am J Kidney Dis*. 2002;39:679–88.
16. Hoy WE, Hughson MD, Singh GR, Douglas-Denton R, Bertram JF. Reduced nephron number and glomerulomegaly in Australian Aborigines: a group at high risk for renal disease and hypertension. *Kidney Int*. 2006;70:104–10.
17. Sterzel RB, Schulze-Lohoff E, Marx M. Cytokines and mesangial cells. *Kidney Int Suppl*. 1993;39:S26–31.
18. Speirs RS. Cells involved in hypersensitivity and immunity. *Blood*. 1963;22:363–7.
19. Neusser MA, Lindenmeyer MT, Moll AG, Segerer S, Edenhofer I, Sen K, Stiehl DP, Kretzler M, Grone HJ, Schlondorff D, Cohen CD. Human nephrosclerosis triggers a hypoxia-related glomerulopathy. *Am J Pathol*. 2010;176:594–607.
20. Hill GS. Hypertensive nephrosclerosis. *Curr Opin Nephrol Hypertens*. 2008;17:266–70.
21. Caetano ER, Zatz R, Saldanha LB, Praxedes JN. Hypertensive nephrosclerosis as a relevant cause of chronic renal failure. *Hypertension*. 2001;38:171–6.
22. Nanayakkara S, Senevirathna STMLD, Karunaratne U, Chandrajith R, Harada KH, Hitomi T, Watanabe T, Abeysekera T, Aturaliya TNC, Koizumi A, Consortium CKDoUA (2011) Evidence of tubular damage in the very early stage of chronic kidney disease of uncertain etiology in the North Central Province of Sri Lanka: a cross sectional study. *Environ Health Prev Med* (in press).

23. Kido T, Nordberg GF, Roels HA. Cadmium-induced renal effects. In: Clinical nephrotoxins: renal injury from drugs and chemicals. 3rd ed, chap 35. New York: Springer Science+Business Media, pp 785–811.
24. Nogawa K, Yamada Y, Honda R, Ishizaki M, Tsuritani I, Kawano S, Kato T. The relationship between itai-itai disease among inhabitants of the Jinzu River basin and cadmium in rice. *Toxicol Lett.* 1983;17:263–6.
25. Bonnell JA, Ross JH, King E. Renal lesions in experimental cadmium poisoning. *Br J Ind Med.* 1960;17:69–80.
26. Barnias G, Boletis J. Balkan nephropathy: evolution of our knowledge. *Am J Kidney Dis.* 2008;52:606–16.
27. Schiller A, Gusbeth-Tatomir P, Pavlovic N, Ferluga D, Spasovski G, Covic A. Balkan endemic nephropathy: a still unsolved puzzle. *J Nephrol.* 2008;21:673–80.
28. Shaohua Z, Ananda S, Ruxia Y, Liang R, Xiaorui C, Liang L. Fatal renal failure due to the Chinese herb “GuanMu Tong” (*Aristolochia manshuriensis*): autopsy findings and review of literature. *Forensic Sci Int.* 2010;199:e5–7.
29. de Jonge H, Vanrenterghem Y. Aristolochic acid: the common culprit of Chinese herbs nephropathy and Balkan endemic nephropathy. *Nephrol Dial Transplant.* 2008;23:39–41.
30. Fuchs R, Peraica M. Ochratoxin A in human kidney diseases. *Food Addit Contam.* 2005;22:53–7.
31. Krogh P, Elling F, Gyrd-Hansen N, Hald B, Larsen AE, Lillchoj EB, Madsen A, Mortensen HP, Ravnskov U. Experimental porcine nephropathy: changes of renal function and structure perorally induced by crystalline ochratoxin A. *Acta Pathol Microbiol Scand A.* 1976;84:429–34.
32. Desalegn B, Nanayakkara S, Harada KH, Hitomi T, Chandrajith R, Karunaratne U, Abeysckera T, Koizumi A, Consortium CKDoUE. Mycotoxin detection in urine samples from patients with chronic kidney disease of uncertain etiology in Sri Lanka. *Bull Environ Contam Toxicol.* 2011;87:6–10.
33. Yang CC, Wu ML, Deng JF. Prolonged hemolysis and methemoglobinemia following organic copper fungicide ingestion. *Vet Hum Toxicol.* 2004;46:321–3.
34. Schuurman M, van Waardenburg D, Da Costa J, Niemarkt H, Leroy P. Severe hemolysis and methemoglobinemia following fava beans ingestion in glucose-6-phosphatase dehydrogenase deficiency: case report and literature review. *Eur J Pediatr.* 2009;168:779–82.
35. Srinivas R, Agarwal R, Jairam A, Sakhuja V. Intravascular haemolysis due to glucose-6-phosphate dehydrogenase deficiency in a patient with aluminium phosphide poisoning. *Emerg Med J.* 2007;24:67–8.
36. Xiong X, Liu J, He W, Xia T, He P, Chen X, Yang K, Wang A. Dose-effect relationship between drinking water fluoride levels and damage to liver and kidney functions in children. *Environ Res.* 2007;103:112–6.