

## Journal Pre-proof

Reply: Introducing special cutaneous “sign” tribute to healthcare workers managing new coronavirus disease (Covid –19) - New additions


Ajith P. Kannangara

PII: S0738-081X(20)30104-8

DOI: <https://doi.org/10.1016/j.clindermatol.2020.05.016>

Reference: CID 7469

To appear in: *Clinics in Dermatology*



Please cite this article as: A.P. Kannangara, Reply: Introducing special cutaneous “sign” tribute to healthcare workers managing new coronavirus disease (Covid –19) - New additions, *Clinics in Dermatology* (2020), <https://doi.org/10.1016/j.clindermatol.2020.05.016>

This is a PDF file of an article that has undergone enhancements after acceptance, such as the addition of a cover page and metadata, and formatting for readability, but it is not yet the definitive version of record. This version will undergo additional copyediting, typesetting and review before it is published in its final form, but we are providing this version to give early visibility of the article. Please note that, during the production process, errors may be discovered which could affect the content, and all legal disclaimers that apply to the journal pertain.

© 2020 Published by Elsevier.

COVID-19: Important Updates and Developments  
Edited by Franco Rongioletti, MD and Leonard J. Hoenig, MD

Title: Reply: Introducing special cutaneous “sign” tribute to healthcare workers managing new coronavirus disease (Covid –19) - New additions.

Authors: Ajith P. Kannangara , MD

Consultant Dermatologist; Ministry of Health;  
Dermatology Unit; Base Hospital – Balapitiya; Sri Lanka.

Phone: 94-718284802 E-mail:  
ajithpkannangara@yahoo.com

Financial Disclosures: None [SEP] Funding: None [SEP] Conflicts of Interest: None

To the Editor:

Following our initial contribution of introducing special cutaneous “sign” tribute to healthcare workers managing new coronavirus disease (COVID –19) and subsequently a few addition by R. Darlenski et al, I would like to clarify my stance on their suggestions.<sup>1,2</sup> we could add the medics those who have sacrificed their lives to fight the Covid 19 pandemic other than the present medical staff who risk their precious lives at present for the same

cause when defining this special sign. This sign mainly considering the classic cutaneous changes following heavy use of personal protective medical equipment on face; hence, no rationale of adding skin lesions elsewhere in the same population, also created by the extensive use of these medical devices as suggested by same authors<sup>3,4</sup>

Finally, the newly introduced special cutaneous sign should be dedicated to the memory of those medical personnel who have sacrificed their precious lives as well as currently serving with the COVID-19 epidemic control and treatment care units possessing peculiar pressure injuries (erythema, deep indentations & ulcerations) on their faces related to the various personal protective equipment they have worn, should be described as manifesting the “Covid 19 MS sign” (MS for Medical Staff.)

Apart from that ,while highly supporting and endorsing the newly described clinical sign by my colleagues both locally and internationally, a few of them were questioning the application of this sign for health care worker and those who have not displayed complete clinical picture of their faces following prolong usage of protective medical equipment. As a result, I would like to add new descriptive term as “Partial COVID 19 MS sign” related to “COVID 19 MS sign” denoted and depicted by following table and pictures (Table 1.) &

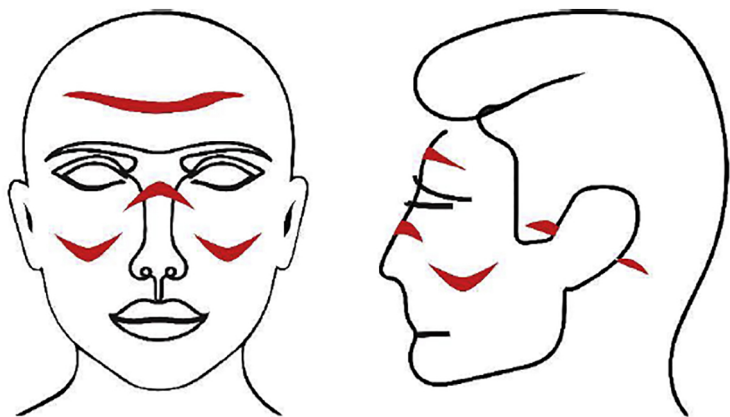
(Picture 1.).

## References

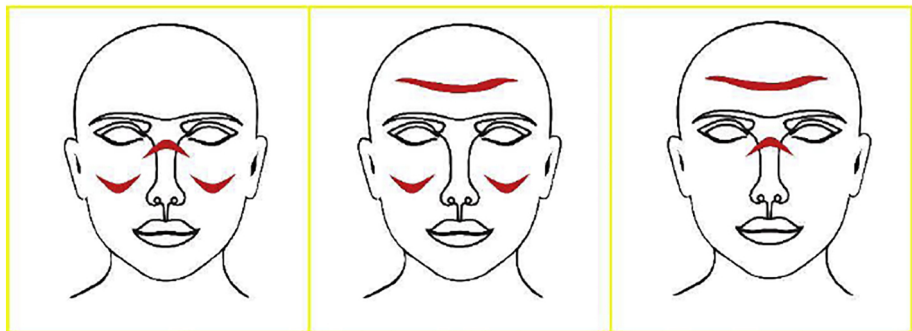
1. R. Darlenski, N. Tsankov Covid-19 pandemic and the skin - What should dermatologists know? Clin Dermatol (2020), <https://doi.org/10.1016/j.clindermatol.2020.03.012>
2. Kannangara K. Introducing special cutaneous “sign” tribute to healthcare workers managing new coronavirus disease (Covid –19), Clin Dermatol (2020), <https://doi.org/10.1016/j.clindermatol.2020.04.009>
3. R. Darlenski and N. Tsankov, Reply: Introducing special cutaneous “sign” tribute to healthcare workers managing new coronavirus disease (Covid –19), Clin Dermatol (2020), <https://doi.org/10.1016/j.clindermatol.2020.04.013>
4. R. Darlenski and N. Tsankov, reply: Introducing special cutaneous “sign” tribute to healthcare workers managing new coronavirus disease (Covid –19), Clin Dermatol (2020), <https://doi.org/10.1016/j.clindermatol.2020.04.012>

<p><b>A. Type of pressure injuries</b></p> <ol style="list-style-type: none"><li>1. Erythema</li><li>2. Deep indentations</li><li>3. Ulcerations</li></ol>
<p><b>B. Sites of facial injury</b></p> <ol style="list-style-type: none"><li>1. Forehead</li><li>2. Bridge of the nose</li><li>3. Cheeks (2 sites)</li><li>4. Retro auricular area (2 sites)</li></ol>
<p><b>C. Point system and definition</b></p> <p>Any of the given injury on mentioned facial site – 1 point Total number of sites are 6 hence, total number of points – 6 points</p> <ul style="list-style-type: none"><li>1-3 points - partial Covid 19 MS Sign</li><li>4-6 points - Covid 19 MS Sign / Complete Covid 19 MS Sign</li></ul>

**Table 1.**



**"Covid 19 MS Sign"**



**"Partial Covid 19 MS Sign"**