

# Early Clinical and CT Manifestations of Coronavirus Disease 2019 (COVID-19) Pneumonia

Rui Han<sup>1</sup>  
Lu Huang<sup>2</sup>  
Hong Jiang<sup>1</sup>  
Jin Dong<sup>1</sup>  
Hongfen Peng<sup>1</sup>  
Dongyou Zhang<sup>1</sup>

**OBJECTIVE.** The purpose of this study was to investigate early clinical and CT manifestations of coronavirus disease (COVID-19) pneumonia.

**MATERIALS AND METHODS.** Patients with COVID-19 pneumonia confirmed by severe acute respiratory syndrome coronavirus 2 (SARS-CoV-2) nucleic acid test (reverse transcription–polymerase chain reaction) were enrolled in this retrospective study. The clinical manifestations, laboratory results, and CT findings were evaluated.

**RESULTS.** One hundred eight patients (38 men, 70 women; age range, 21–90 years) were included in the study. The clinical manifestations were fever in 94 of 108 (87%) patients, dry cough in 65 (60%), and fatigue in 42 (39%). The laboratory results were normal WBC count in 97 (90%) patients and normal or reduced lymphocyte count in 65 (60%). High-sensitivity C-reactive protein level was elevated in 107 (99%) patients. The distribution of involved lobes was one lobe in 38 (35%) patients, two or three lobes in 24 (22%), and four or five lobes in 46 (43%). The major involvement was peripheral (97 patients [90%]), and the common lesion shape was patchy (93 patients [86%]). Sixty-five (60%) patients had ground-glass opacity (GGO), and 44 (41%) had GGO with consolidation. The size of lesions varied from smaller than 1 cm (10 patients [9%]) to larger than 3 cm (56 patients [52%]). Vascular thickening (86 patients [80%]), crazy paving pattern (43 patients [40%]), air bronchogram sign (52 patients [48%]), and halo sign (69 [64%]) were also observed in this study.

**CONCLUSION.** The early clinical and laboratory findings of COVID-19 pneumonia are low to midgrade fever, dry cough, and fatigue with normal WBC count, reduced lymphocyte count, and elevated high-sensitivity C-reactive protein level. The early CT findings are patchy GGO with or without consolidation involving multiple lobes, mainly in the peripheral zone, accompanied by halo sign, vascular thickening, crazy paving pattern, or air bronchogram sign.

**Keywords:** clinical manifestations, coronavirus, COVID-19, CT, pneumonia, SARS-CoV-2

doi.org/10.2214/AJR.20.22961

R. Han and L. Huang contributed equally to this study.

Received February 13, 2020; accepted without revision February 15, 2020.

<sup>1</sup>Department of Radiology, Wuhan No. 1 Hospital, Zhongshan Ave 215, Wuhan, 430022, China. Address correspondence to D. Zhang (826038415@qq.com).

<sup>2</sup>Department of Radiology, Tongji Hospital, Tongji Medical College, Huazhong University of Science and Technology, Wuhan, China.

AJR 2020; 215:1–6

ISSN-L 0361–803X/20/2152–1

© American Roentgen Ray Society

**C**oronavirus disease (COVID-19) pneumonia is caused by severe acute respiratory syndrome coronavirus 2 (SARS-CoV-2), which has an envelope and granules [1–3]. It first appeared in Wuhan, Hubei, China. It is highly infectious and spreads through respiratory droplets, contact, and the fecal-oral route. It is characterized by acute onset, severe symptoms, and serious threat to human health and safety. Therefore, the World Health Organization listed this pneumonia epidemic of Wuhan, China, as a public health emergency of international concern. According to the most recent diagnosis and treatment plan for COVID-19 pneumonia issued by the National Health Commission of the People's Republic of China (trial version 5), the disease is diagnosed mainly from epidemiologic factors, clinical manifestations, CT findings, and nu-

cleic acid detection of SARS-CoV-2. The most important change in trial version 5 was that cases with the combination of clinical suspicion and CT findings of pneumonia can be diagnosed as clinically confirmed cases. The purpose of this study was to assess the early clinical and CT manifestations of COVID-19 pneumonia to provide important reference values for early diagnosis, early prevention, and early treatment.

## Materials and Methods

### Patients

This retrospective study received local ethics committees approval. Patients with confirmed COVID-19 pneumonia confirmed by SARS-CoV-2 nucleic acid test (reverse transcription–polymerase chain reaction) at our hospital (Wuhan No. 1 Hospital) from January 4 to February 3, 2020, were enrolled in this retrospective

**TABLE 1: Clinical Manifestations of Coronavirus Disease (COVID-19) Pneumonia (n = 108)**

Clinical Manifestation	No.
Fever	94 (87)
Dry cough	65 (60)
Fatigue	42 (39)
Chest distress	17 (16)
Diarrhea	15 (14)
Pharyngeal pain	14 (13)
Headache	14 (13)
Muscle pain	12 (11)

Note—Values in parentheses are percentages.

study. The inclusion criteria were as follows: no history of other lung infectious disease, initial CT examination performed in our department after the onset of disease, and patient condition classified as mild COVID-19 pneumonia according to the China National Health Commission Notice on Issuing a New Coronavirus Infected Pneumonia Diagnosis and Treatment Plan (trial version 5) [4]. The exclusion criteria were CT examination performed as follow-up for patients with COVID-19 pneumonia and chest CT image quality insufficient for image analysis.

The clinical symptoms—that is, fever, dry cough, fatigue, chest distress, diarrhea, pharyngeal pain, headache, and muscle pain—and time from onset to CT examination were recorded from the clinical history. The laboratory results (routine blood tests, high-sensitivity C-reactive protein measurement) were also observed.

### CT

All chest CT examinations were performed with a BrightSpeed (GE Healthcare) or Somatom Definition Flash (Siemens Healthineers) scanner. The patient was in supine position and performing a breath-hold after inhalation. The scanning range was from bilateral apex to base. The scanning parameters were as follows: helical scanning mode; tube voltage, 120 kV; tube current–time product, 50–350 mAs; pitch, 1.2 and 1.375; matrix, 512 × 512; slice thickness, 10 mm; reconstructed in lung window; reconstructed slice thickness, 1.25 mm.

### CT Analysis

Two radiologists with more than 5 years' experience in chest imaging analyzed all CT images independently. If there was any inconsistency, they reached agreement through discussion. A third radiologist (25 years of experience in pulmonary imaging diagnosis) reviewed all CT find-

**TABLE 2: Laboratory Findings of Coronavirus Disease (COVID-19) Pneumonia (n = 108)**

Laboratory Test	No. Normal	No. Reduced	No. Elevated
WBC count	97 (90)	11 (10)	0
Lymphocyte count	43 (40)	65 (60)	0
High-sensitivity C-reactive protein level	1 (1)	0	107 (99)

Note—Values in parentheses are percentages.

ings for confirmation. The following CT features were assessed: distribution (peripheral, central, or central and peripheral), number of lobes involved (one, two or three, four or five), shape (patchy, nodular), appearance (ground-glass opacity [GGO], consolidation, or GGO with consolidation), specific signs of foci (vascular thickening, crazy paving pattern, air bronchogram sign, halo sign, and fibrosis), size of largest focus (< 1 cm, 1–3 cm, > 3 cm), and extrapulmonary manifestations (mediastinal and hilar lymph node enlargement, pleural effusion, pleural thickening).

### Results

#### Clinical Characteristics

A total of 108 patients with mild COVID-19 pneumonia (38 men, 70 women; age range, 21–90 years; mean, 45 years) were enrolled in this study. The time from onset of symptoms to CT examination was 1–3 days (median, 1 day). The patients had various clinical symptoms (Table 1). Ninety-four of 108 (87%) patients had fever (body temperature, 37.3–38.5°C). The distribution of laboratory findings is shown in Table 2. All 108 patients had a normal or decreased WBC count. The lymphocyte count was decreased in 65 (60%) patients and normal in 43 (40%) patients. An elevated high-sensitivity C-reactive protein level was found in 107 patients (99%).

#### CT Findings

The CT findings of the 108 patients are shown in Table 3. Seventy (65%) patients had involvement of two or more lobes, and 97% of lesions were located in the peripheral zone of the lung. When a single lobe was involved, the right lower lobe was most often affected (30/38 [79%]). The most common CT features (Figs. 1 and 2) were patchy GGO (86%) and GGO with consolidation (41%). Eighty-six (80%) patients had vascular thickening (Figs. 3 and 4), and 43 (40%) had the crazy paving pattern (Fig. 4). The air bronchogram sign (Figs. 3 and 5) was visualized in 52 (48%) patients and the halo sign in 69 (64%) (Figs. 2 and 5). Most (68/108 [63%]) of the lesions were larger

than 1 cm. No patient had mediastinal or hilar lymph node enlargement, pleural effusion, or pleural thickening.

**TABLE 3: Early CT Features of Coronavirus Disease (COVID-19) Pneumonia**

High-Resolution CT Feature	No.
Distribution of lesions in lung	
Peripheral	97 (90)
Central	2 (2)
Peripheral and central	9 (8)
No. of lobes	
1	38 (35)
2 or 3	24 (22)
4 or 5	46 (43)
Shape of lesions	
Patchy	93 (86)
Nodular	12 (11)
Appearance of lesions	
Ground-glass opacity	65 (60)
Consolidation	6 (6)
Ground-glass opacity with consolidation	44 (41)
Specific signs	
Vascular thickening	86 (80)
Crazy paving pattern	43 (40)
Air bronchogram sign	52 (48)
Fibrosis	0
Halo sign	69 (64)
Size of the single largest lesion (cm)	
< 1	10 (9)
1–3	42 (39)
> 3	56 (52)
Extrapulmonary manifestations	
Mediastinal and hilar lymph node enlargement	0
Pleural effusion	0
Pleural thickening	0

Note—Values in parentheses are percentages.

### Discussion

By February 13, 2020, nearly 60,000 cases of COVID-19 pneumonia had been diagnosed in China and more than 1300 patients had died, and there were confirmed reports of the disease in other countries. How to stop spread of the pandemic has become an urgent problem. It is critical to detect and diagnose COVID-19 pneumonia early and to immediately isolate and treat the patient. Although SARS-CoV-2 nucleic acid detection is the reference standard, it has a high false-negative rate due to nasopharyngeal swab sampling error, which often requires repeated samples. Many patients delay treatment, causing spread of the disease because of delay in diagnosis. High-resolution CT can depict millimeter-size lesions and play an important role in early diagnosis of viral pneumonia [5], including COVID-19 pneumonia [6, 7].

COVID-19 pneumonia is common in adults (mean age, 45 years) but rare in children and infants. In this study, the early clinical symptoms varied; fever, dry cough, and fatigue were common. Ninety-four of 108 (87%) patients had low to midgrade fever (range, 37.3–38.5°C), which was followed in frequency by dry cough (60%) and fatigue (39%). Laboratory results showed the characteristics of viral infection, such as normal or decreased WBC count (100%) and decreased lymphocyte count (60%). Almost all (99%) patients had an elevated high-sensitivity C-reactive protein level due to inflammation.

Early CT findings showed that the lesions involved two or more lobes and were mainly distributed in the peripheral zone of the lung. In 38 (35%) patients only a single lobe was involved, usually the right lower lobe. This

finding may be related to the anatomy of the right lower lobe bronchus, which is thick and short, making it easy for the virus to invade it. Early lesions were rarely consolidated (6/108 [6%]). Fairly characteristic manifestations were vascular thickening (80%), halo sign (64%), crazy paving pattern (40%), and air bronchogram sign (48%).

Why are GGO and the halo sign early CT manifestations? The pathophysiologic mechanism is not clear. It may be similar to those of other coronavirus infections, such as SARS-CoV and Middle East respiratory syndrome coronavirus (MERS-CoV). The inflammatory cytokine storm causes pneumonia. The early pathologic finding in this study was diffuse alveolar damage. Because the hyaline membrane is between the alveolar walls, exudation and edema in the alveoli are not obvious [8], possibly causing GGO on CT images. Fibrosis and extrapulmonary manifestations, such as enlargement of mediastinal and hilar lymph nodes, pleural effusion, and pleural thickening, are not present in early lesions of COVID-19 pneumonia. These findings may be seen in the later phase and severe type of the disease.

There were limitations to this study. First, there was no follow-up CT to evaluate early treatment efficacy. Study is ongoing to validate our prediction. Second, lung tissue biopsies to investigate our hypothesis on the relation between CT and histopathologic manifestations were not available.

### Conclusion

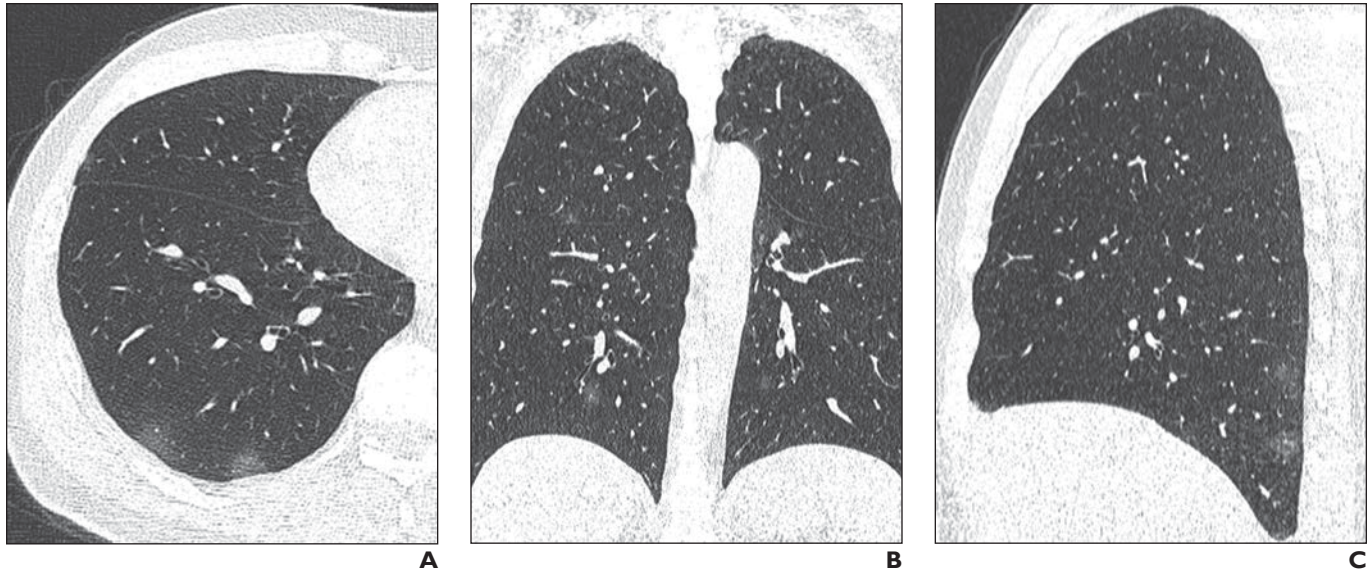
The early common clinical symptoms of COVID-19 pneumonia are low to midgrade fever, dry cough, and fatigue. The early CT

features are multiple patchy pure GGOs or GGO with consolidation in the peripheral zone of the lung, often with vascular thickening and the crazy paving pattern, air bronchogram sign, or halo sign.

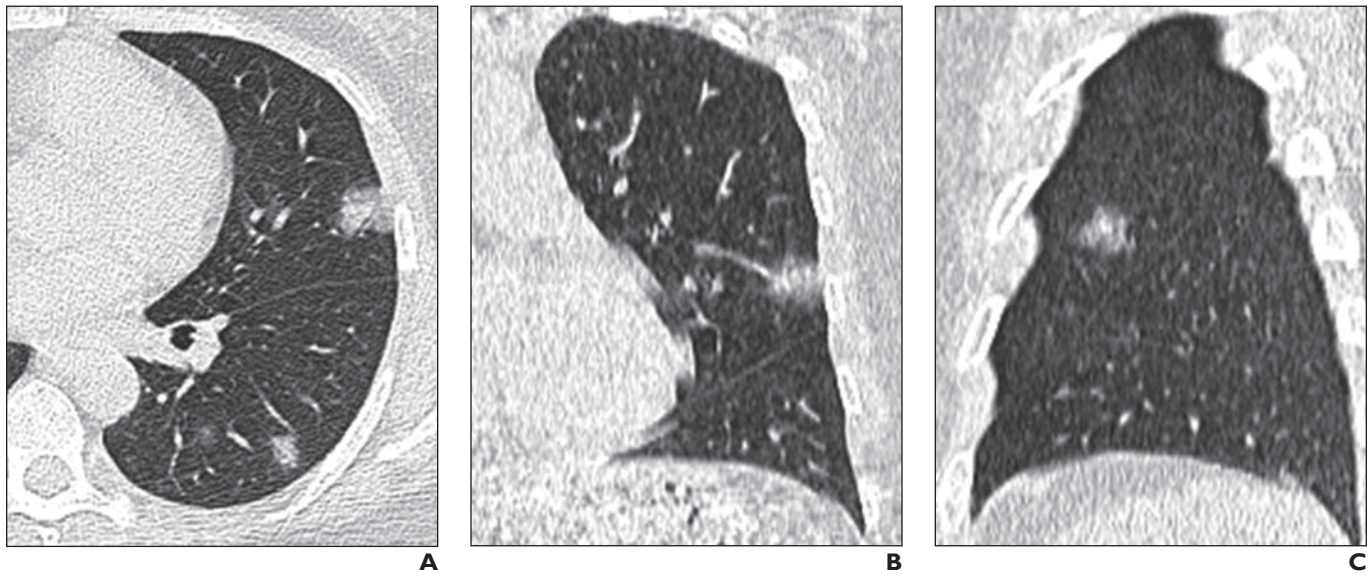
### References

1. Li Q, Guan X, Wu P, et al. Early transmission dynamics in Wuhan, China, of novel coronavirus-infected pneumonia. *N Engl J Med* 2020 Jan 29 [Epub ahead of print]
2. Chen N, Zhou M, Dong X, et al. Epidemiological and clinical characteristics of 99 cases of 2019 novel coronavirus pneumonia in Wuhan, China: a descriptive study. *Lancet* 2020; 395:507–513
3. Chu DKW, Pan Y, Cheng SMS, et al. Molecular diagnosis of a novel coronavirus (2019-nCoV) causing an outbreak of pneumonia. *Clin Chem* 2020 Jan 31 [Epub ahead of print]
4. China National Health Commission website. Notice on issuing a new coronavirus infected pneumonia diagnosis and treatment plan (trial version 5). [bgs.satcm.gov.cn/zhengcewenjian/2020-02-06/12847.html](http://bgs.satcm.gov.cn/zhengcewenjian/2020-02-06/12847.html). Published February 4, 2020. Accessed February 18, 2020
5. Paul NS, Roberts H, Butany J, et al. Radiologic pattern of disease in patients with severe acute respiratory syndrome: the Toronto experience. *RadioGraphics* 2004; 24:553–563
6. Chung M, Bernheim A, Mei X, et al. CT imaging features of 2019 novel coronavirus (2019-nCoV). *Radiology* 2020 Feb 4 [Epub ahead of print]
7. Holshue ML, DeBolt C, Lindquist S, et al.; Washington State 2019-nCoV Case Investigation Team. First case of 2019 novel coronavirus in the United States. *N Engl J Med* 2020; 382:929–936
8. Huang C, Wang Y, Li X, et al. Clinical features of patients infected with 2019 novel coronavirus in Wuhan, China. *Lancet* 2020; 395:497–506

(Figures start on next page)

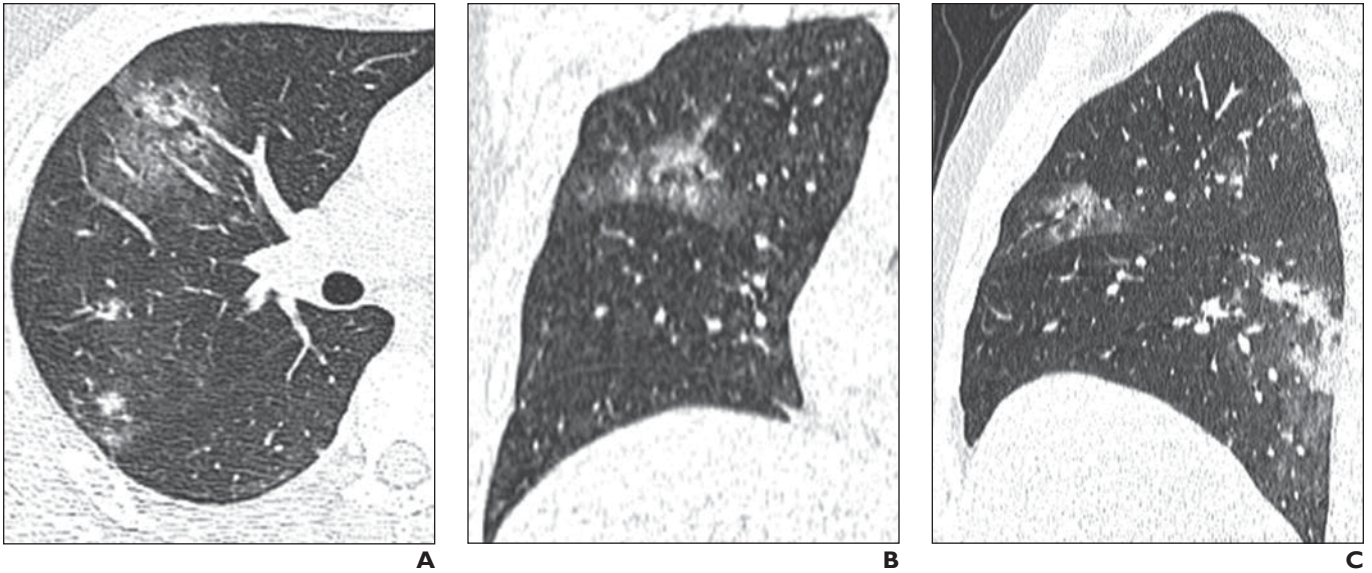


**Fig. 1**—50-year-old man with fever and dry cough. **A–C**, Axial (**A**), coronal (**B**), and sagittal (**C**) CT images show scattered patchy ground-glass opacity in peripheral aspect of both lungs and poor definition of area surrounding lesions.



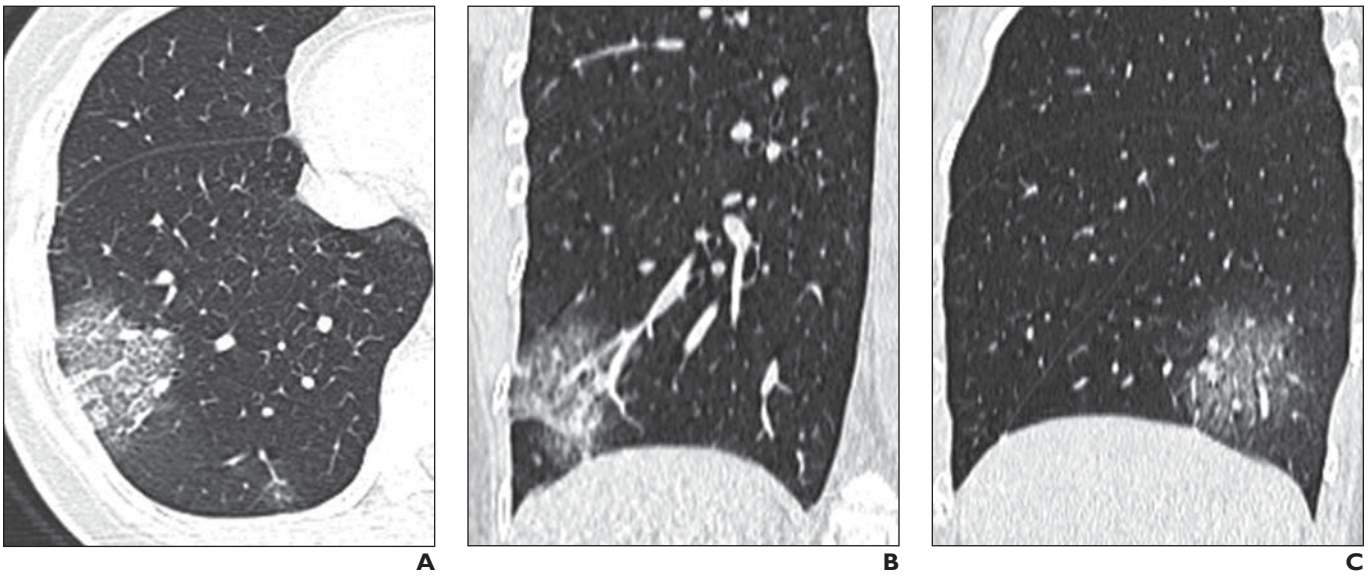
**Fig. 2**—44-year-old woman with fever and fatigue. **A–C**, Axial (**A**), coronal (**B**), and sagittal (**C**) CT images of left lung show scattered ground-glass opacity with consolidation and accompanying halo sign. Largest lesion measures 1–3 cm.

## Early Clinical and CT Manifestations of COVID-19 Pneumonia



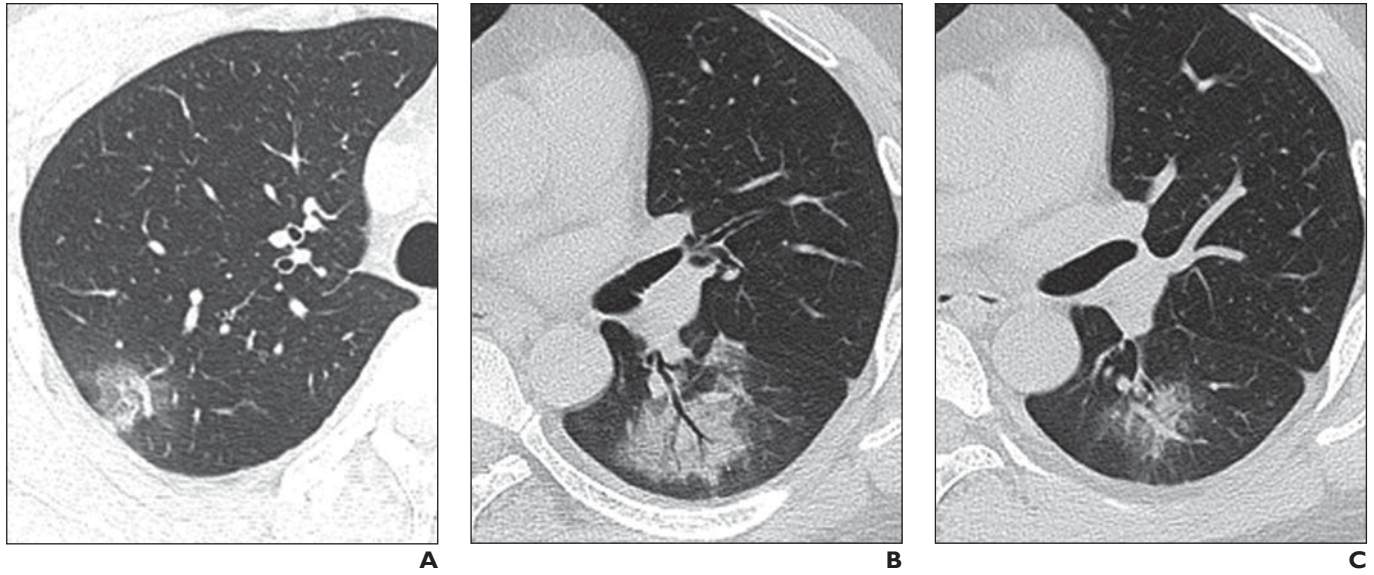
**Fig. 3**—35-year-old man with fever, dry cough, and fatigue.

**A–C**, Axial (**A**), coronal (**B**), and sagittal (**C**) CT images of right lung show multiple patchy ground-glass opacities with consolidation scattered in peripheral zone of lower lobe, poorly defined boundary, air bronchogram sign, and vascular thickening. Largest lesions are larger than 3 cm.



**Fig. 4**—40-year-old woman with dry cough, fatigue, and diarrhea.

**A–C**, Axial (**A**), coronal (**B**), and sagittal (**C**) CT images of right lung show multiple patchy ground-glass opacities with consolidation scattered in peripheral zone of lower lobe, poorly defined boundary, vascular thickening, and crazy paving pattern. Largest lesions are larger than 3 cm.



**Fig. 5**—35-year-old man with fever, fatigue, and myalgia.

**A–C**, Axial CT scans show patchy ground-glass opacities with consolidation in peripheral zones of both lower lobes, poorly defined boundary, air bronchogram sign (**B**), and vascular thickening (**A, C**). Largest lesions, seen in **B**, are larger than 3 cm.