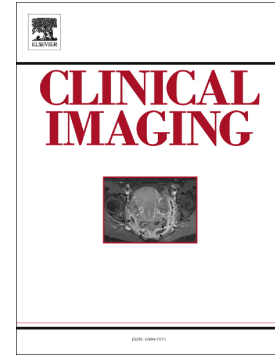

Journal Pre-proof

Peripheral arterial occlusion due to COVID-19: CT angiography findings of nine patients

Makoto Ogawa, Florence X. Doo, Alexander S. Somwaru, Alexandra Roudenko, Amita Kamath, Barak Friedman



PII: S0899-7071(20)30454-X

DOI: <https://doi.org/10.1016/j.clinimag.2020.11.023>

Reference: JCT 9157

To appear in: *Clinical Imaging*

Received date: 29 July 2020

Revised date: 10 October 2020

Accepted date: 13 November 2020

Please cite this article as: M. Ogawa, F.X. Doo, A.S. Somwaru, et al., Peripheral arterial occlusion due to COVID-19: CT angiography findings of nine patients, *Clinical Imaging* (2018), <https://doi.org/10.1016/j.clinimag.2020.11.023>

This is a PDF file of an article that has undergone enhancements after acceptance, such as the addition of a cover page and metadata, and formatting for readability, but it is not yet the definitive version of record. This version will undergo additional copyediting, typesetting and review before it is published in its final form, but we are providing this version to give early visibility of the article. Please note that, during the production process, errors may be discovered which could affect the content, and all legal disclaimers that apply to the journal pertain.

© 2018 Published by Elsevier.

Title:

Peripheral arterial occlusion due to COVID-19: CT angiography findings of nine patients

Authors:

1. Makoto Ogawa, MBBS, MS (Makoto.Ogawa@mountsinai.org)
2. Florence X. Doo, MD (Florence.Doo@mountsinai.org)
3. Alexander S. Somwaru, MD (Alexander.Somwaru@mountsinai.org)
4. Alexandra Roudenko, MD (Alexandra.Roudenko@mountsinai.org)
5. Amita Kamath, MD (Amita.Kamath@mountsinai.org)
6. Barak Friedman, MD (Barak.Friedman@mountsinai.org)

Affiliations:

Department of Radiology, Icahn School of Medicine at Mount Sinai, New York, NY, USA

Contact Info:

ATTN: Makoto Ogawa, MBBS, MS

Department of Radiology

Mount Sinai West

1000 10th Ave, New York NY 10019

Makoto.Ogawa@mountsinai.org

(212) 523 - 8333

No Funding Sources and no disclosures for any author.

Abstract**Background**

Reports have indicated an association of large vessel peripheral arterial occlusion in the setting of Coronavirus Disease 2019 (COVID-19). While prior investigations have mostly focused on venous or cerebral arterial occlusions, we examined patients presenting exclusively with peripheral arterial extremity occlusions to investigate for any predisposing factors in this subset of COVID-19 patients.

Materials and methods

This is a retrospective study of COVID-19 patients with peripheral arterial occlusions presenting to a multi-hospital health care system in New York City between February 1st, 2020 and April 30th, 2020. Patient data and computed tomography angiography (CTA) exams in this subset were then collected and analyzed.

Results

For the months of February, March, and April 2020, we identified 9 patients (ages 37-93yrs) at our health care system who underwent extremity CTA for large vessel upper or lower extremity arterial occlusion and were diagnosed with COVID-19. Patient medical histories and clinical parameters were evaluated to identify common risk factors including obesity, hypertension, hyperlipidemia, and diabetes. Patients presented with increased inflammatory markers including ferritin, erythrocyte sedimentation rate (ESR) and C-reactive protein (CRP) as well as increased D-dimer.

Conclusion

Our findings suggest patients with COVID-19 and comorbidities presenting with elevated inflammatory markers and D-dimer may be at increased risk of large vessel peripheral arterial occlusion.

Introduction

The novel severe acute respiratory syndrome coronavirus 2 (SARS-CoV-2) which causes COVID-19 has been found to induce a prothrombotic state manifesting in an increased incidence of venous thrombosis, acute coronary syndrome, and large vessel strokes [1, 2]. Reports have suggested an increased incidence of acute extremity large vessel arterial occlusions with COVID-19 [3], which could result in limb loss. This led our team to investigate this phenomenon to assess common risk factors that could potentially lead to early screening for high risk patients. We identified 9 patients who presented to our healthcare system emergency rooms between February and April of 2020 with lower or upper extremity large vessel arterial occlusion in the setting of COVID-19.

Materials and Methods

This was a retrospective institutional review board approved and Health Insurance Portability and Accountability Act (HIPAA) compliant study performed at a multi-hospital healthcare system in New York City. All extremity CTA exams between February 1st 2020 and April 30th 2020 were queried and those patients screened for concurrent SARS-CoV-2 infection. All adult patients (≥ 18 years old) with large vessel occlusion and confirmed COVID-19 were included in the study.

CTA imaging technique varied slightly between hospitals and scanners but included unenhanced images through the legs to evaluate for below the knee calcifications, thin section arterial phase imaging (0.625 mm to 1.25 mm) usually from the lung bases to the feet utilizing bolus tracking

(150 HU threshold of the aorta at L1), immediately followed by repeat imaging from the mid thigh to the feet to exclude unopacified vessels due to scanner outrunning the bolus. 125 mL iodinated contrast (iohexol 350 mg iodine/mL [Omnipaque 350, GE healthcare]) was administered at a rate of 4 mL/second. In patients with renal dysfunction, no adjustments in contrast amount was made. Complete imaging sets were reviewed including multiplanar reformats and volume rendered imaging by a single radiologist with 17 years experience in body and vascular imaging (BF). The length of the arterial occlusions were recorded and classified as a short segment occlusion (<10 cm), intermediate length occlusion (10 to 20 cm), or long segment occlusion (>20 cm). The extent of atherosclerotic calcification at the occluded segment was evaluated as absent, mild, moderate, or severe based on a method previously described by Portugaller et al [4]. If the lungs were partially imaged, the pulmonary findings were categorized as typical, indeterminate, atypical, or negative as per the Radiological Society of North America Consensus statement on Reporting Chest CT Findings Related to COVID-19 [5]. All patients were diagnosed with SARS-CoV-2 infection using rapid polymerase chain reaction tests. Patient charts were reviewed for medical history, medications, inflammatory and coagulation labs, intervention, and outcomes.

Results

A summary of the results is provided in Table 1. Nine patients [3 male, 6 female, age 37-93 (average age 71)] were admitted with large vessel extremity arterial occlusion in the setting of COVID-19 between the months of February and April 2020. In total, the health care system cared for approximately 6,690 inpatients during this time and another 4355 patients through the emergency department who did not need to be admitted. This totals to 11,045 patients diagnosed with COVID-19 during this time period of which 9 individuals were diagnosed with acute

extremity arterial occlusion on CTA. The incidence of extremity arterial occlusion by CTA amongst patients with COVID-19 was roughly 0.08%. Hypertension was the most common comorbidity (8/9 patients), followed by obesity (4/9) and insulin dependent diabetes (2/9). Two of the patients were taking anticoagulation medication, one for a history of CVA and the other for a history of atrial fibrillation. None of the patients had a history of an underlying hypercoagulable disorder. The most common patient complaint was extremity pain (6/9). One of the patients sustained multiple embolic cerebral infarcts in addition to the extremity arterial occlusion (Patient 3). None of the other eight patients were found to have an additional site of vascular occlusion other than the extremity arterial occlusions described.

In eight of the patients, CRP, D-dimer, and Ferritin were tested with CRP and D-dimer elevated in all eight patients and Ferritin elevated in seven. ESR was elevated in all six patients tested.

White blood cell count was elevated in six of the nine patients.

A majority of the patients (6/9) had long segment lower extremity arterial occlusions (Fig 1) with one having bilateral lower extremity long segment occlusions. One of those six patients had two segments of occlusion in the same lower extremity (one short and another long). One patient had bilateral lower extremity intermediate length arterial occlusions, and another patient had a single side lower extremity intermediate length arterial occlusion. Another patient had two short segments of upper extremity arterial occlusion (Fig 2).

Calcific atherosclerotic disease was relatively common with 4 of 9 patients with moderate or severe disease and 5 of 9 patients with none or mild disease. Only one patient had a prior lower extremity arterial intervention with stents and presented with a long segment occlusion of the stents extending from the left distal femoral artery to the popliteal artery (Fig 3). Seven patients had a portion of the lungs included in the imaging with five of these patients having typical

imaging findings for COVID-19 pneumonia. In patients with typical findings for COVID-19 pneumonia at the lung bases, the lengths of occlusion ranged from 3 cm to 83 cm with a mean of 33.4 cm. In the patient with atypical findings of COVID-19 pneumonia, the length of occlusion was 98 cm, and in the patient with no pulmonary findings for pneumonia, there were two intermediate length occlusions measuring 18 cm and 20 cm.

Two patients, both of whom had long segment arterial occlusions, required surgical amputation of the affected limb. Another patient declined intervention for palliative care. Five patients were managed with thrombectomy and two patients were treated with anticoagulation alone.

Discussion

To our knowledge this is the first study of large vessel peripheral extremity arterial occlusion in patients with COVID-19. The majority of our patients had associated comorbidities with hypertension and obesity being the most common. Most patients also had typical pulmonary findings of COVID pneumonia in the visualized lung bases. The length of arterial occlusion did not correlate with the severity of pneumonia. All patients with lower extremity arterial occlusions had at least one occlusive segment longer than 10 cm which was readily apparent on all multiplanar reformats as well as volume rendered imaging. We found that pre-existing calcific atherosclerotic disease is not a necessary factor in the development of COVID related arterial occlusion. Though the incidence is low, most of our patients that developed large vessel extremity arterial occlusion required invasive interventions such as open thrombectomy or amputation.

The mechanism of action is theorized to be in part due to systemic inflammatory changes and direct endothelial damage caused by SARS-CoV-2 induced endotheliitis [5, 6]. This theory is supported by the presence of increased ESR and CRP in this patient population.

While this is the first study to examine this phenomenon in this novel disease, our study has inherent limitations. In addition to the biases of a retrospective study, this study is also limited by looking only at CTAs. If patients had been taken to the operating room immediately without a CTA for a suspected ischemic limb, this large vessel occlusion would not have been identified. Therefore, the incidence of extremity arterial occlusions in COVID-19 could be higher than what we report. Another limitation is having one unblinded radiologist view the images which creates bias and does not allow for evaluation of interobserver variability. However, we felt the arterial occlusions would be readily apparent to radiologists with vascular imaging experience.

Conclusion

Peripheral extremity arterial occlusion can be a presenting feature of COVID-19. Patients with a history of obesity or hypertension, with increased inflammatory markers and elevated D-dimer are potentially at increased risk. This observation suggests consideration for a lower threshold for performing CTAs on these patients, particularly if presenting with extremity symptoms.

Additional studies with larger patient numbers are indicated to further study patients at risk for extremity arterial occlusion in COVID-19 and to evaluate which therapy may be most beneficial for this patient population

References

- [1] T. J. Oxley *et al.*, “Large-Vessel Stroke as a Presenting Feature of Covid-19 in the Young,” *N. Engl. J. Med.*, 2020, doi: 10.1056/NEJMc2009787.
- [2] R. O. Bonow, G. C. Fonarow, P. T. O’Gara, and C. W. Yancy, “Association of Coronavirus Disease 2019 (COVID-19) with Myocardial Injury and Mortality,” *JAMA Cardiology*. 2020, doi: 10.1001/jamacardio.2020.1105.
- [3] F. A. Klok *et al.*, “Incidence of thrombotic complications in critically ill ICU patients with COVID-19,” *Thromb. Res.*, 2020, doi: 10.1016/j.thromres.2020.04.013.
- [4] H. R. Portugaller, H. Schoellnast, K. A. Hausegger, M. Tiesenhäuser, W. Amann, and A. Berghold, “Multislice spiral CT angiography in peripheral arterial occlusive disease: A valuable tool in detecting significant arterial lumen narrowing?,” *European Radiology*. 2004, doi: 10.1007/s00330-004-2284-1
- [5] S. Simpson *et al.*, “Radiological Society of North America Expert Consensus Statement on Reporting Chest CT Findings Related to COVID-19. Endorsed by the Society of Thoracic Radiology, the American College of Radiology, and RSNA,” *Radiol. Cardiothorac. Imaging*, 2020, doi: 10.1148/ryct.2020200152.
- [6] B. Bikdeli *et al.*, “COVID-19 and Thrombotic or Thromboembolic Disease: Implications for Prevention, Antithrombotic Therapy, and Follow-up,” *J. Am. Coll. Cardiol.*, 2020, doi: 10.1016/j.jacc.2020.04.031.
- [7] C. Magro *et al.*, “Complement associated microvascular injury and thrombosis in the pathogenesis of severe COVID-19 infection: a report of five cases,” *Transl. Res.*, 2020, doi: 10.1016/j.trsl.2020.04.007.

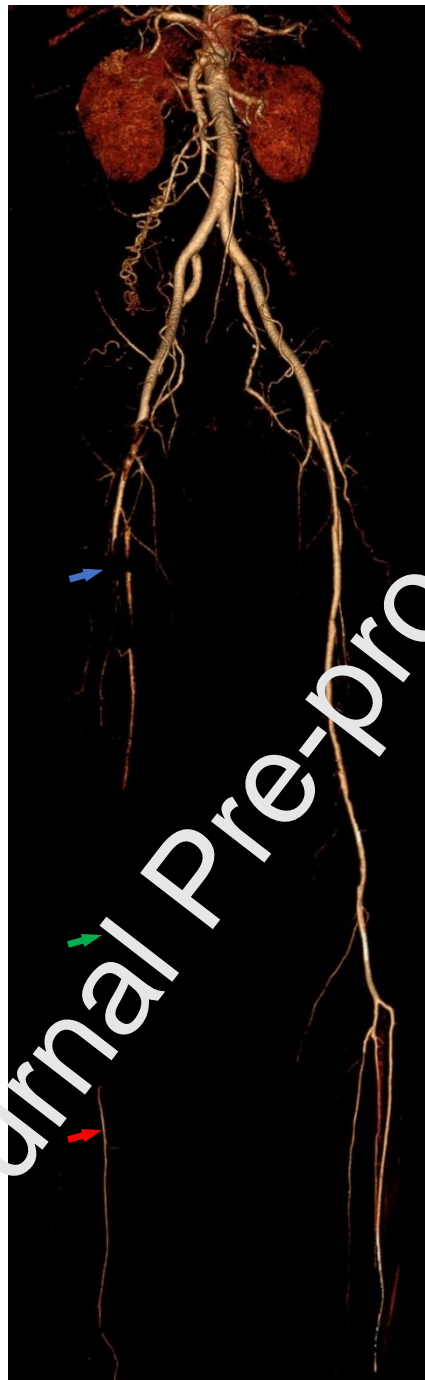


Fig 1. Lower extremity CTA volume rendered 3D reconstruction of a 37 year old female demonstrates long segment occlusion of the right femoral artery (blue arrow), popliteal artery (green arrow), posterior tibial artery and peroneal artery. The right anterior tibial artery remains patent (red arrow).

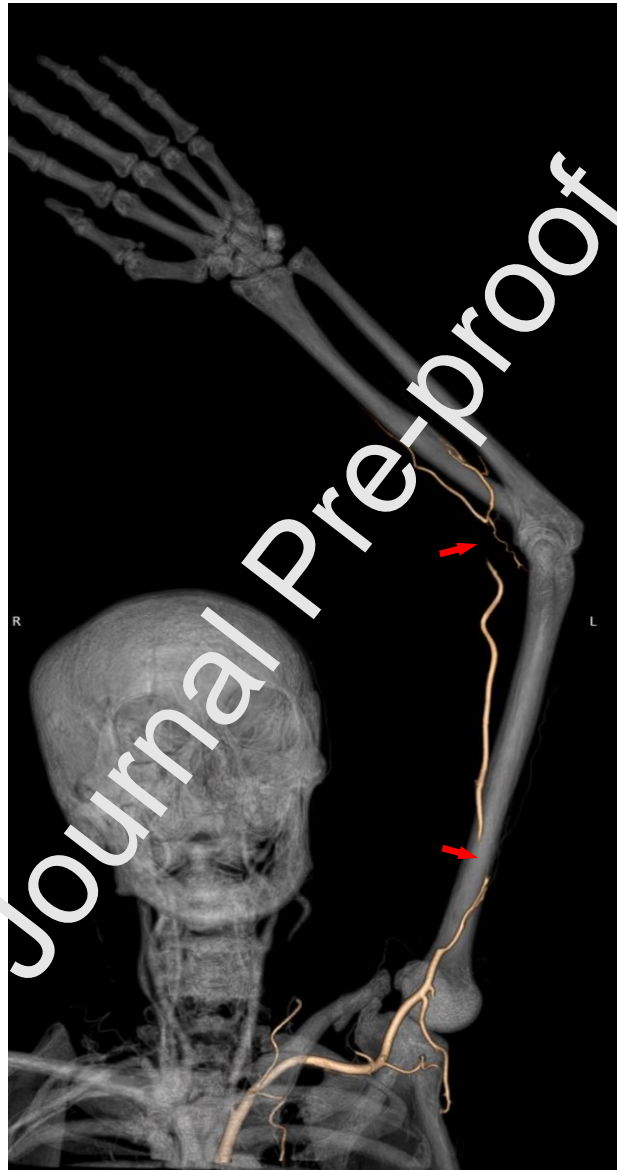


Fig 2. CTA volume rendered 3D reconstruction from an 80 year old female demonstrates two short segment left upper extremity brachial artery occlusions (red arrows).

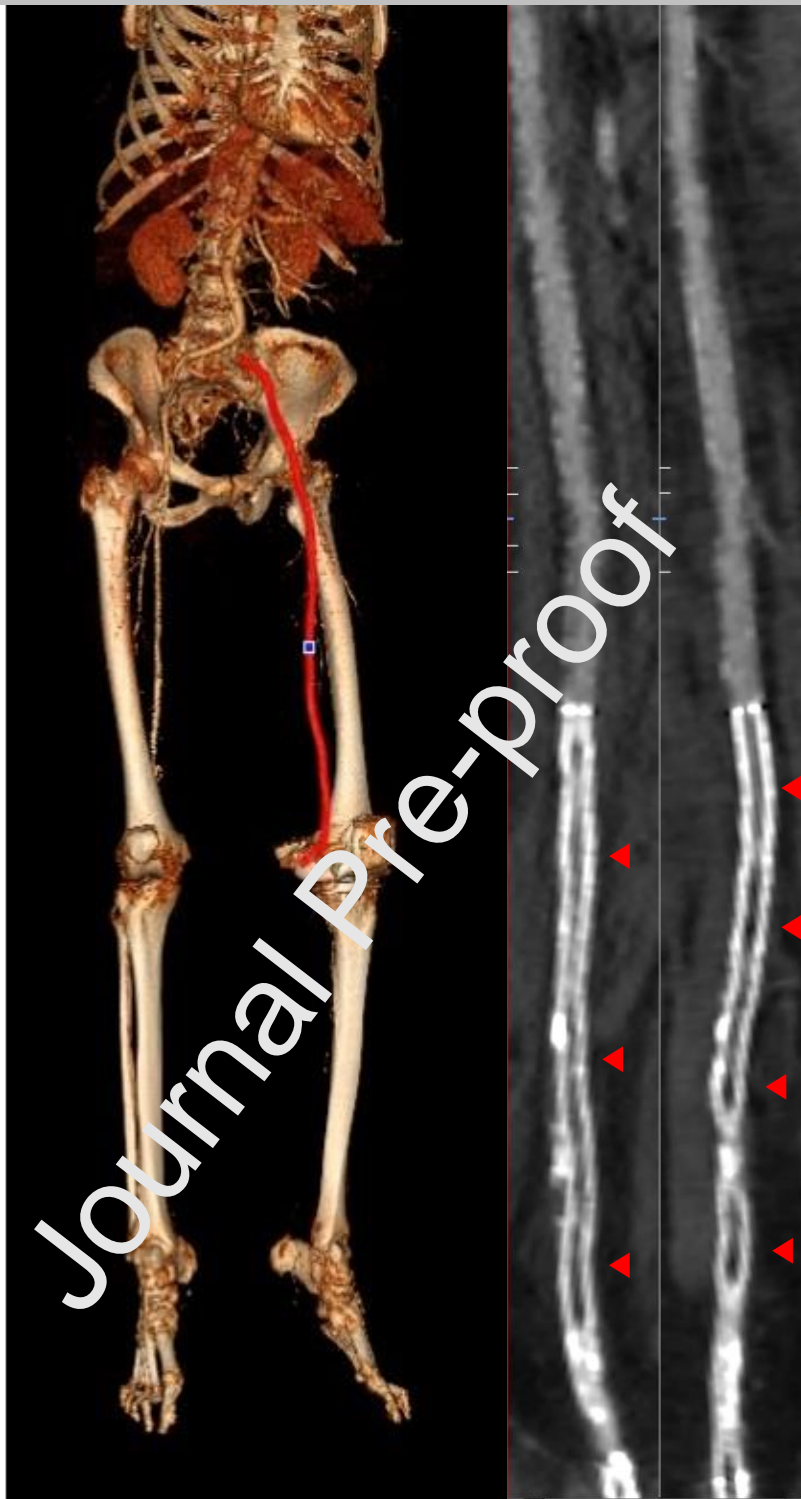


Fig 3. Lower extremity CTA volume rendered 3D reconstruction (image on left) with a red line indicating the vessel course used for two oblique curved reformats perpendicular to each other (two images on right) in a 68 year old female demonstrates long segment in-stent occlusion of the left distal femoral and popliteal artery stents (red arrowheads).

Variable	Patient 1	Patient 2	Patient 3	Patient 4	Patient 5	Patient 6	Patient 7	Patient 8	Patient 9
Age - yr	38	37	80	84	68	77	69	93	89
Sex	Male	Female	Female	Male	Female	Male	Female	Female	Female
Medical history and risk factors	Hypertension, Obese	Obese, Hypertension, Diabetes, Cerebral vascular accident	Atrial fibrillation, Hyperlipidemia	Atrial fibrillation, Hypertension, Hyperlipidemia	Obese, Diabetes, Hypertension	Obese, Hypertension, Hyperlipidemia, Rheumatoid arthritis	Hypertension, Hyperlipidemia, Rheumatoid arthritis	No past medical history	Hypertension
Home Medications	Losartan	Chlorthalidone, Clopidogrel	Apixiban	Metformin, Pravastatin, Amlodipine-Olmesartan	Ibuprofen, Insulin, Levofloxacin, Simvastatin	Hydrochlorothiazide, Tamsulosin, Methotrexate	Amlodipine, Insulin	None reported	None reported
Atherosclerosis	None	None	None	Mild	Moderate	Mild	Moderate	Severe	Moderate
COVID symptoms	Cough x 1 week	Dry cough and fever x 1 week	Diagnosed with COVID 1 week prior	Fever and SOB x 2 weeks	Cough and SOB several days	Congestion and rhinorrhea x 2 weeks	Lack of appetite x 2 days	Altered mental status	Altered mental status
Time of COVID diagnosis to presentation?	Time of presentation	Time of presentation	1 week prior	1 week prior	Time of presentation	1 week prior	Time of presentation	Time of presentation	Time of presentation
Imaging of Lung Bases for COVID-19	Typical	Typical	Typical	Not included	Typical	Typical	Not included	Atypical. Pleural effusions and atelectasis.	No evidence for pneumonia.
Extremity symptoms	Right leg pain and right foot swelling x 9 days.	Acute onset right foot pain x 1 day.	Left upper extremity numbness & weakness x 1 hour	Sudden onset cold left lower extremity.	Transferred from rehab facility with worsening foot pain and discoloration.	Sudden onset left leg pain and numbness 1 week after admission.	Worsening left leg pain and weakness x 2 days.	Transferred from nursing home and found to have lower extremity erythema,	Pain when ambulating on right leg.

								left greater than right, and cold to touch.	
								98 cm (long segment)	18 cm (intermediate length) occlusion of the entire left lower extremity from the common iliac artery to the feet.
Imaging of extremities	18 cm (intermediate length) occlusion from the right popliteal artery to the posterior tibial artery.	77 cm (long segment) occlusion from the right proximal femoral artery to the feet.	6 cm and 3.4 cm (two short segments) occlusions in the left brachial artery and distal brachial artery respectively.	3 cm and 52 cm (short and long segment) occlusions in the left common iliac artery and from the left popliteal artery to the feet respectively.	25 cm (long segment) occlusion of the left distal femoral artery and popliteal artery stents.	83 cm (long segment) occlusion of the entire left lower extremity from the common femoral artery to the feet.	85 cm (long segment) occlusion of the entire left lower extremity from the common femoral artery to the feet.	85 cm (long segment) occlusion of the entire left lower extremity from the common femoral artery to the feet.	18 cm (intermediate length) occlusion involving the left distal femoral artery and popliteal artery. Additional 20 cm (intermediate length) occlusion involving the right distal femoral and popliteal arteries.
Intervention	Popliteal artery cutdown, thrombectomy	Heparin infusion, thrombolysis, thrombectomy	Anticoagulation	Thrombectomy, fasciotomies	Left below knee amputation	Cut down, thrombectomy	Balloon angioplasty, cutdown, thrombectomy and above knee amputation	No intervention, palliative	Anticoagulation
Outcome	Discharged on anti-coagulation	Discharged on anticoagulation	Discharged on anticoagulation	Prolonged hospitalization	Discharged on anti-coagulation	Discharged on anti-coagulation	Discharged on anti-coagulation	Death	Discharged on anticoagulation
White-cell count – per mm³ (4500 –	11,900	10,700	12,000	10,000	21,100	13,800	23,000	14,800	6,400

11000 mm³)									
Platelet count – per mm³									
(150,000 – 450,000 mm³)	370,000	429,000	563,000	325,000	613,000	323,000	427,000	313,000	228,000
Prothro mbin time – sec (12-14.2 sec)	13.3	14.6	13.9	16.9	18.6	15.2	15.8	15.7	14.8
Fibrinog en – mg/dl (212-516 mg/dL)	-	389	515	336	531	-	897	524	-
D-dimer – ng/ml (0.0 - 500 ng/ml FEU)	820	>20,000	8210	>20,000	2510	6080	>20,000	2610	-
Ferritin – ng/ml (15 - 150 ng/ml)	86	232	395	464	1024	2055	2489	164	-
Erythro cyte sedimen tation rate – mm/hr (0-20 mm/hr)	-	-	30	59	94	69	75	54	-
C- reactive protein – mg/L (0.0 - 5.0 mg/L)	15.2	62	37.6	171.3	75.1	56.5	234.2	41	-

Highlights

- Peripheral extremity arterial occlusion can be a presenting feature of COVID-19.
- Patients with a history of obesity or hypertension, with increased inflammatory markers and elevated D-dimer are potentially at increased risk of peripheral extremity arterial occlusion in COVID-19.
- A lower threshold for performing CTAs on patients with COVID-19 should be considered, particularly if they present with extremity symptoms.

Journal Pre-proof